

A HANDBOOK OF LANDMARK TRIALS



A TNOA EDITORIAL INITIATIVE

6 / 60
6 / 36
6 / 24
6 / 12
6 / 9
6 / 6

LENS

LANDMARK EVIDENCE NUMBERS SUMMARIES

IN OPHTHALMOLOGY

The trials that shaped eye care, distilled for vivas, journal clubs and postgraduate teaching

Author & Editor, LENS

Dr Pranessh Ravi

MS, DNB, MNAMS, FMRF (Cornea),MRCS, FRCS (Glasgow),FAICO (Cornea), FAICO (Refractive) Cornea and Phaco-Refractive Consultant
The Eye Foundation, Hosur

Executive Editor, LENS I Editor-In-Chief, TNOA

Dr Prasanna Venkatesh Ramesh

MS (Gold Medalist), DNB, FACS, MNAMS, FAICO (Glaucoma), FICO (Glaucoma), FAICO (Cataract/Phaco-Gold Medalist), Glaucoma Surgery and Research Fellow (dr sathyan's)



Forewords

Prof. Dr. V. R. Vijayaraghavan • **Dr. D. Chandrasekhar**



In POAG, Ocular hypertension, Secondary glaucoma

India's 1st Rx

Ripatec

Ripasudil 0.4%

Eye Drops

OPHTHALMOLOGIST TRUSTED

Addresses the disease pathology

24 HRS IOP CONTROL

BID Dose

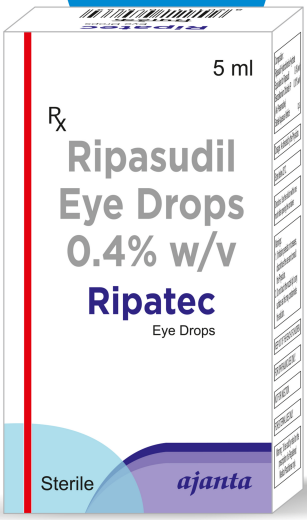

ajanta pharma limited

INYX
Hope for vision

A HANDBOOK OF LANDMARK TRIALS

LENS

LANDMARK · **E**VIDENCE · **N**UMBERS · **S**UMMARIES
IN OPHTHALMOLOGY

The trials that shaped eye care, distilled for vivas, journal clubs and postgraduate teaching

EXAM REVISION EDITION

Author & Editor, LENS

Dr Pranessh Ravi

MS, DNB, MNAMS, FMRF (Cornea), MRCS,
FRCS (Glasgow), FAICO (Cornea), FAICO (Refractive)

Consultant, Cornea & Phaco-Refractive Surgery
The Eye Foundation, Hosur, Tamil Nadu, India

Executive Editor, LENS | Editor-In-Chief, TNOA

Dr Prasanna Venkatesh Ramesh

MS (Gold Medalist), DNB, FACS, MNAMS, FAICO (Glaucoma),
FICO (Glaucoma), FAICO (Cataract/Phaco-Gold Medalist),
Glaucoma Surgery and Research Fellow (dr sathyan's)

Glaucoma Medical Officer & Research Director,
Mahathma Eye Hospital Pvt Ltd, Trichy, Tamil Nadu, India

TNOA Managing Committee 2026-27



Dr V R Vijayaraghavan
President



Dr Sujatha Mohan
Immediate Past President



Dr V Madhavan
President Elect



Dr Kalpana Suresh
Vice President



Dr D Chandrasekhar
Hon. General Secretary



Dr M R Sriram Gopal
Hon. Treasurer



Dr Prasanna V Ramesh
Editor-In-Chief



Dr M Ravishankar
Chairman, ARC



Dr S Jeyanthan
Joint Secretary



Dr Sathian Nagamalai
Joint Treasurer

TNOA Managing Committee Members 2025-28



Dr Sundar D



Dr J K Reddy



Dr C Balasubramaniam



Dr S Sozhamadevi



Dr Parthiban Purushothaman



Dr Vanaja Vaithianathan



Dr K Kavitha Lakshmi



Dr B Koshal Ram



Dr M Chockalingam



Dr Pratheeba Devi Nivean



Dr Vinoth Arunachalam



Dr Divya Manohar



Dr T Vimala



Dr Aadithreya Varman



Dr Niranjan Karthik Senthil Kumar

FOREWORD

I have spent much of my working life sitting across the table from postgraduates, at the bedside, in the viva room and in exam-oriented sessions up and down the country. Over the years one question has told me more about a candidate than almost any other: “What is the evidence for what you just said?”

A well-prepared candidate does not merely cite “ETDRS” or “Protocol T”. Rather, they demonstrate a clear understanding of the study population, the interventions compared, the magnitude of the observed differences, and the limitations of the trial. Others may recall the acronym without fully appreciating the evidence it represents. This distinction seldom reflects a difference in intellectual ability; more often, it underscores the need for an accessible, structured, and reliable resource through which these landmark trials can be understood in their proper scientific and clinical context.

This book fills that gap. Dr. Prasanna Venkatesh Ramesh and Dr. Pranessh Ravi have taken the trials every resident is expected to know and reduced each one to its essentials: the design, the question, the answer, what changed in practice, and the trap an examiner is waiting to set. The chapters run by subspecialty and by year, so the reader sees how each field grew, from photocoagulation to anti-VEGF, from trabeculectomy to laser-first glaucoma care. The figures have been checked against the original papers, and every chapter ends with references for those who want to go back to the source, as they should.

Through TNOA’s postgraduate training programmes, I have always believed that the young ophthalmologist must be given good tools early. This is one such tool. I would urge every resident to read it twice: once before the examination, and once again after it, when the trials stop being answers to questions and start becoming reasons for decisions in the clinic.

I congratulate Dr. Prasanna Venkatesh Ramesh and Dr. Pranessh Ravi, and I am glad that this work has come from within our own Association.

Prof. Dr. V. R. Vijayaraghavan
President, Tamil Nadu Ophthalmic Association

FOREWORD

The true stature of a professional association is discerned not merely in the conferences it convenes, but in the intellectual contributions it fosters and the spirit of collegiality it cultivates. Scholarly contributions by the TNOA Editorial Board beyond TJOSR will serve to enlighten, enrich, and empower the ophthalmic fraternity, stand as a testament to the Association's steadfast commitment to academic distinction, intellectual advancement, and professional excellence.

This book is practical in the best sense. It does not try to be a textbook. It takes nearly a hundred landmark trials across thirteen chapters, presents each in the same five lines, and leaves the reader with what matters: the result, its weakness, and its place in practice today. Separate chapters for the DRCR.net protocols and for emerging therapies, guideline boxes where the evidence has become policy, and a reference list at the end of every chapter make it as useful to the consultant preparing a talk as to the resident preparing for an examination.

Much of the Association's enduring contribution lies in its sustained commitment to institutional development, professional collaboration, and the cultivation of meaningful connections among its members. A book such as this reflects the value of that collective effort, bringing together members who learn from one another, share their knowledge, and contribute to the professional growth of their colleagues.

On behalf of the Tamil Nadu Ophthalmic Association, I congratulate Dr. Prasanna Venkatesh Ramesh and Dr. Pranessh Ravi and commend this book to our members and to postgraduates everywhere.

Dr. D. Chandrasekar
Honorary Secretary, Tamil Nadu Ophthalmic Association

TNOA Editor-In-Chief's Note

Evidence-based medicine forms the foundation of contemporary ophthalmic practice. Understanding landmark clinical trials is essential not only for postgraduate examinations but also for translating scientific evidence into informed clinical decisions.

LENS (Landmark, Evidence, Numbers, Summaries) In Ophthalmology: The Evidence That Changed Practice is a valuable educational initiative that brings together pivotal studies across ophthalmic subspecialties in a concise, structured, and examination-oriented format. By highlighting key findings, clinical implications, and important limitations, this book bridges the gap between published research and practical learning.

As Editor-In-Chief of the TNOA Journal of Ophthalmic Science and Research, I strongly believe in promoting scientific literacy, critical appraisal, and evidence-based clinical practice among young ophthalmologists.

I congratulate Dr. Pranessh Ravi on this commendable academic collaboration with TNOA editorial team and hope this book serves as a useful reference for postgraduate students, young ophthalmologists, and practising clinicians.

Dr. Prasanna Venkatesh Ramesh
Executive Editor, LENS | Editor-In-Chief, TNOA

PREFACE

This book started with a problem we kept running into. Every time a trial came up in teaching or discussion, we would go digging for the same papers again. We knew the names, and we roughly knew what they showed. But ask us the actual number, or exactly what was compared with what, and we had to go back to the paper.

The trials themselves are not hard. They are hard to hold. A paper runs to fifteen pages and a few supplementary appendices, and at the end of it you really need four things: what they asked, what they found, what changed because of it, and where the examiner will try to catch you out. Everything else can wait.

So this is a short book with a long list of trials, and every trial gets the same five lines: the question, the answer with the one number worth remembering (in bold), what it changed in practice, the exam trap, and, where practice has moved on, where things stand now. One line under each heading gives the design: what was compared, in whom, how many and for how long. You should be able to read an entry in under a minute and still recall it a month later.

The trials are grouped by subspecialty, because that is how we meet them in clinic. Each chapter opens with a story line showing how one trial led to the next, because examiners ask the sequence as often as the trials. Within each chapter the trials run in order of year, and the DRCR.net protocols get a chapter of their own. Each trial is headed by the short name everyone actually uses, like ONTT or EAGLE. The year is when the main paper came out; if the number people quote comes from a later report, both years are given.

A word on the numbers and the text. The figures are taken from standard texts and checked against the original papers. Each entry is written as a distillation of the original study: much shorter, but without losing its essence.

This is not a systematic review. It is the book we wanted next to us. If it sends you back to the original paper, especially for a trial you are going to quote, then it has done its job.

Dr Pranessh Ravi
Author & Editor, LENS

HOW TO USE THIS BOOK

Before a viva. Read the story line at the top of the chapter, then the Answer and Exam trap for every trial in your weak subspecialty. It takes about twenty minutes and covers most of what gets asked.

Before a journal club. Read the study snapshot and the Answer, then open the actual paper and check the numbers yourself. Use this book to know where to look, not as the source.

Before consenting a patient. Read the Answer and the Exam trap. That is usually where the honest uncertainty sits.

If you have five minutes. Just read the bold numbers and the Changed practice line. That is what each trial gave us.

HOW EACH ENTRY IS LAID OUT

- **Study snapshot:** what was compared, in whom, how many, for how long.
- **Question:** what the trial asked.
- **Answer:** what it found, with the one number worth remembering in bold.
- **Changed practice:** what it contributed.
- **Exam trap:** the caveat or mix-up examiners like to test.
- **Now:** where practice has since moved on (only where relevant).

A NOTE ON THE EVIDENCE

- Numbers are given the way the trial reported them. Where there were several doses or arms, they follow the same order as the paper.
- This is a study aid, not a guideline. For real patients, goby current college and national guidance and the primary papers.

- Revised November 2026: every entry was checked again against its original paper and written up in this five-line format.

TABLE OF CONTENTS

Foreword 7
Preface 13
How To Use This Book 15
Contents 17
Age-Related Macular Degeneration 19
Retinal Vein Occlusion 33
Myopic Cnv And Central Serous Chorioretinopathy 43
Diabetic Retinopathy And Diabetic Macular Oedema 47
DRCR.Net Protocols 59
Glaucoma 65
Cataract Surgery 73
Cornea And Ocular Surface 77
Uveitis 83
Paediatric Ophthalmology And Strabismus 89
Vitreoretinal Surgery 95
Neuro-Ophthalmology 101
Emerging Therapies 107

1

AGE-RELATED MACULAR DEGENERATION

Wet AMD is the disease where treatment changed twice: first photodynamic therapy, then anti-VEGF. Examiners test what was compared with what, and whether monthly, PRN or extended dosing won. The dry AMD trials are asked differently: who actually benefits from supplements, and what the new complement inhibitors for geographic atrophy do and do not achieve.

STORY LINE Wet AMD: TAP (PDT works, but only in predominantly classic CNV) → VIP (occult CNV, weak benefit) → VISION (first anti-VEGF: slows loss) → FOCUS (ranibizumab + PDT beats PDT) → ANCHOR and MARINA (ranibizumab alone improves vision in all lesion types) → PIER/EXCITE, PRONTO, SUSTAIN (how often to inject?) → CATT and IVAN (bevacizumab works as well) → VIEW (aflibercept every 8 weeks) → HAWK/HARRIER and TENAYA/LUCERNE (longer intervals); EVEREST for PCV. Dry AMD: AREDS (zinc and antioxidants slow progression to advanced AMD) → AREDS2 (lutein and zeaxanthin replace beta carotene) → GATHER1/2 and OAKS/DERBY (complement inhibitors slow geographic atrophy, not vision loss).

NEOVASCULAR (WET) AMD

TAP

1999

Treatment of Age-related macular degeneration with Photodynamic therapy

STUDY SNAPSHOT

Verteporfin PDT vs placebo · 609 patients · subfoveal CNV with a classic component · 12 months

QUESTION	Does PDT prevent vision loss in subfoveal CNV?
ANSWER	Yes, but only in **predominantly classic** lesions: **67% vs 39%** lost fewer than 15 letters (all lesions 61% vs 46%).
CHANGED PRACTICE	First effective treatment for subfoveal CNV that did not burn the fovea. Made lesion composition on angiography the basis for treatment.

EXAM TRAP The predominantly classic benefit is a subgroup result; minimally classic lesions showed no significant benefit.

NOW No longer used alone for typical AMD. Survives as an adjunct in PCV and at half dose in chronic CSCR.

VIP

2001

Verteporfin In Photodynamic therapy

STUDY SNAPSHOT

Verteporfin PDT vs placebo · 339 patients(258 Occult + 81 early classic) · occult CNV with no classic component · 24 months

QUESTION	Does PDT help occult CNV, which TAP did not study?
ANSWER	Not at 12 months (primary endpoint missed). At 24 months **54% vs 67%** lost 15 letters or more.
CHANGED PRACTICE	Briefly extended PDT to occult CNV.

EXAM TRAP The benefit in smaller lesions or worse acuity was a subgroup finding, and the confirmatory VIO trial failed. Acute severe vision loss within a week occurred in 4.4% of treated eyes.

NOW Obsolete.

VISION

2004

VEGF Inhibition Study In Ocular Neovascularization

STUDY SNAPSHOT

Pegaptanib 0.3, 1 or 3 mg vs sham every 6 weeks · 1,186 patients · all lesion types · 54 weeks

QUESTION	Does blocking VEGF inside the eye help wet AMD?
ANSWER	It **slowed loss**: **70% vs 55%** lost fewer than 15 letters (0.3 mg). Mean vision still fell.
CHANGED PRACTICE	First anti-VEGF trial: proof of concept for the whole anti-VEGF era.

EXAM TRAP Pegaptanib preserved vision; it did not improve it. Ranibizumab was the first drug to improve vision on average.

NOW Obsolete. Pegaptanib(Macugen) blocks one VEGF isoform($VEGF_{165}$); current drugs block all of VEGF-A.

FOCUS

2006

RhuFab V2 Ocular Treatment Combining the Use of Visudyne to Evaluate Safety

STUDY SNAPSHOT

Ranibizumab + PDT vs sham injection + PDT · 162 patients · predominantly classic CNV · phase I/II

QUESTION	Does adding ranibizumab to PDT help?
ANSWER	Yes: **90.5% vs 67.9%** lost fewer than 15 letters at 12 months.
CHANGED PRACTICE	Little. ANCHOR soon showed ranibizumab did not need PDT at all.

EXAM TRAP Combination therapy was never standard for typical AMD, and FOCUS did not change practice. Serious intraocular inflammation occurred in 11.4% with the early formulation.

ANCHOR

2006

Anti-VEGF Antibody for the Treatment of Predominantly Classic Choroidal Neovascularization in AMD

STUDY SNAPSHOT

Monthly ranibizumab 0.3 or 0.5 mg vs PDT · 423 patients · predominantly classic CNV · 12 months

QUESTION	Can ranibizumab replace PDT?
ANSWER	Yes: **+11.3 letters vs −9.5** at 1 year (0.5 mg); 96% vs 64% lost fewer than 15 letters; **40% vs 6%** gained 15 letters.
CHANGED PRACTICE	With MARINA, made anti-VEGF first-line and showed for the first time that vision in wet AMD could improve.

EXAM TRAP ANCHOR = predominantly classic CNV vs **PDT**. MARINA = occult or minimally classic CNV vs **sham**.

MARINA

2006

Minimally Classic/Occult Trial of the Anti-VEGF Antibody Ranibizumab in the Treatment of Neovascular AMD

STUDY SNAPSHOT

Monthly ranibizumab 0.3 or 0.5 mg vs sham · 716 patients · minimally classic or occult CNV · 24 months

QUESTION	Does ranibizumab work in the lesions PDT could not treat?
ANSWER	Yes: **+7.2 letters vs −10.4** at 1 year (0.5 mg), maintained at 2 years; 95% vs 62% lost fewer than 15 letters.
CHANGED PRACTICE	Showed anti-VEGF works across all lesion types, so lesion composition no longer decides treatment.

EXAM TRAP The comparator was sham, not PDT.

PIER 2008 & EXCITE 2011

PIER: a Phase IIIb, multicenter, randomized, double-masked, sham injection-controlled study of ranibizumab in subfoveal CNV secondary to AMD. EXCITE: trial name, not an abbreviation (Efficacy and safety of monthly versus quarterly ranibizumab in neovascular AMD).

STUDY SNAPSHOT

Ranibizumab monthly ×3 then quarterly · PIER (184 patients) vs sham; EXCITE (353 patients) vs monthly · 12 months

QUESTION	Can maintenance be stretched to every three months after loading?
ANSWER	Not for most eyes. In PIER about **4.5 letters** were lost between months 3 and 12 on quarterly dosing (still far better than sham, −16.3); in EXCITE monthly gained **+8.3 letters vs +4.9 and +3.8** for quarterly.
CHANGED PRACTICE	Established that fixed quarterly dosing is inadequate and pushed practice towards individualised regimens.

EXAM TRAP EXCITE was a non-inferiority trial that **failed to show non-inferiority**; that is not the same as proving quarterly dosing inferior.

PRONTO

2009

Prospective OCT Imaging of Patients with Neovascular AMD Treated with intraOcular Lucentis

STUDY SNAPSHOT

Ranibizumab ×3 then OCT-guided PRN · 40 patients · uncontrolled, open-label cohort · 24 months

QUESTION	Can OCT-guided retreatment hold vision with fewer injections?
ANSWER	Year 1: **+9.3 letters with 5.6 injections**. Year 2: +11.1 letters with 9.9 injections in total (about 5 a year).
CHANGED PRACTICE	Introduced OCT-guided PRN dosing.

EXAM TRAP No control arm: PRONTO showed feasibility, not equivalence to monthly dosing.

SUSTAIN

2011

Trial name, not an abbreviation. Full title: Study of ranibizumab in patients with subfoveal choroidal neovascularization secondary to AMD.

STUDY SNAPSHOT

Ranibizumab ×3 then PRN · 513 patients · open-label single-arm phase III · 12 months

QUESTION	Does PRN after loading work at scale?
ANSWER	Safe, but the gain peaked at +5.8 letters (month 3) and settled at **+3.6 letters** at 12 months, after a mean of 2.7 retreatments.
CHANGED PRACTICE	Showed that infrequent PRN retreatment lets the early gain erode.

EXAM TRAP Single-arm, **not an RCT**.

CATT

2011/2012

Comparison of Age-related Macular Degeneration Treatments Trials

STUDY SNAPSHOT

Ranibizumab 0.5 mg vs bevacizumab 1.25 mg, monthly or PRN · 1,208 patients · 2 years

QUESTION	Is bevacizumab as good as ranibizumab, and does PRN match monthly?
ANSWER	Drugs equivalent: monthly **+8.5 vs +8.0 letters** at 1 year. At 2 years PRN gained slightly less than monthly (about 2.4 letters).
CHANGED PRACTICE	Gave level-one evidence for low-cost bevacizumab worldwide.

EXAM TRAP Serious systemic adverse events, mostly hospitalisations, were commoner with bevacizumab (24.1% vs 19.0%) at 1 year but spread across disease categories; In 2 years, death, MI and stroke were similar.

EVEREST

2012

Trial name, not an abbreviation. Full title: Efficacy and safety of verteporfin PDT in combination with ranibizumab or alone versus

ranibizumab monotherapy in symptomatic macular polypoidal choroidal vasculopathy.

STUDY SNAPSHOT

PDT + ranibizumab vs PDT alone vs ranibizumab alone · 61 patients · polypoidal choroidal vasculopathy · 6 months

QUESTION	What closes polyps in PCV?
ANSWER	Complete polyp regression (primary endpoint): **77.8%** combination, 71.4% PDT alone, **28.6%** ranibizumab alone.
CHANGED PRACTICE	Showed that PDT is needed to close polyps.

EXAM TRAP Acuity differences between arms were not significant in EVEREST; the acuity question was settled by EVEREST II.

NOW EVEREST II (322 patients, 2017): combination beat ranibizumab alone (+8.3 vs +5.1 letters; polyp regression 69.3% vs 34.7%; median 4 vs 7 injections).

IVAN

2012/2013

Inhibition of VEGF in Age-related choroidal Neovascularisation

STUDY SNAPSHOT

Ranibizumab vs bevacizumab, continuous or discontinuous · 610 patients · UK · 2×2 factorial · 2 years

QUESTION	The UK version of CATT.
ANSWER	At the 2-year primary analysis, bevacizumab minus ranibizumab **−1.37 letters** (95% CI −3.75 to 1.01): neither non-inferior nor inferior. Discontinuous dosing lost a little efficacy.
CHANGED PRACTICE	With CATT, established the drugs as similar in efficacy.

EXAM TRAP Mortality was lower with continuous dosing (OR 0.47); arterial thrombotic events did not differ by drug. The 1-year result (−1.99 letters) was also inconclusive.

VIEW 1 AND VIEW 2

2012

VEGF Trap-Eye: Investigation of Efficacy and Safety in Wet AMD

STUDY SNAPSHOT

Aflibercept 2 mg 8-weekly (after 3 loading doses), 2 mg monthly or 0.5 mg monthly vs monthly ranibizumab · 2,419 patients · 52 weeks

QUESTION	Can aflibercept match monthly ranibizumab at 8-weekly intervals?
ANSWER	Yes: **95–96%** of every aflibercept arm vs **94.4%** with ranibizumab lost fewer than 15 letters; mean gains within 0.5 letters.
CHANGED PRACTICE	Introduced 8-weekly maintenance.

EXAM TRAP Non-inferiority (10% margin), not superiority. Only 2 mg monthly in VIEW 1 was superior (+10.9 vs +8.1 letters).

HAWK AND HARRIER

2020

Trial names, not abbreviations (phase 3 trials of brolucizumab).

STUDY SNAPSHOT

Brolucizumab 6 mg (and 3 mg in HAWK) vs aflibercept 2 mg 8-weekly · 1,817 patients · 48 weeks

QUESTION	Can brolucizumab extend intervals to 12 weeks?
ANSWER	Non-inferior for vision (+6.6 vs +6.8 and +6.9 vs +7.6 letters); **56% and 51%** stayed on 12-weekly dosing; drier retinas.
CHANGED PRACTICE	Showed a longer-acting drug could keep vision with fewer injections.

EXAM TRAP **Retinal vasculitis and occlusive vasculitis** emerged after approval(was also seen in Re-analysis) and now limit its use.

TENAYA AND LUCERNE

2022

Trial names, not abbreviations (phase 3 trials of faricimab).

STUDY SNAPSHOT

Faricimab up to 16-weekly vs aflibercept 8-weekly · 1,329 patients, two phase 3 non-inferiority RCTs · primary endpoint averaged over weeks 40, 44 and 48

QUESTION	Can a dual Ang-2/VEGF-A blocker extend intervals to 16 weeks?
ANSWER	Non-inferior for vision (**+5.8 vs +5.1** and +6.6 vs +6.6 letters); about **80%** reached 12- or 16-weekly dosing (45% on 16-weekly).
CHANGED PRACTICE	Made 16-weekly dosing a realistic target.

EXAM TRAP Faricimab was not shown superior for vision; its advantage is interval length.

NOW Treat-and-extend has replaced fixed and PRN regimens. Aflibercept 8 mg (PULSAR, 2024) and biosimilars are now in use.

DRY AMD AND SUPPLEMENTS

AREDS

2001

Age-Related Eye Disease Study

STUDY SNAPSHOT

Antioxidants, zinc, both or placebo · 3,640 participants in the AMD trial (4,757 in AREDS overall) · about 6 years

QUESTION	Do supplements slow progression of AMD?
ANSWER	In categories 3 and 4, antioxidants plus zinc cut progression to advanced AMD by **about 25%** (5-year risk 28% → 20%) and 15-letter loss by **about 19%**.
CHANGED PRACTICE	Defined who should take supplements: intermediate AMD, or advanced AMD in one eye. Formula: vitamin C 500 mg, vitamin E 400 IU, beta carotene 15 mg, zinc 80 mg, copper 2 mg.

EXAM TRAP No benefit could be shown in early AMD (category 2), because too few eyes progressed.

NOW Replaced by the AREDS2 formula; never give beta carotene to current or former smokers.

AREDS 2

2013

Age-Related Eye Disease Study 2

STUDY SNAPSHOT

Lutein 10 mg/zeaxanthin 2 mg, omega-3 1 g, both or placebo, added to AREDS variants · 4,203 participants · 5 years

QUESTION	Do other nutrients improve on the AREDS formula?
ANSWER	No added benefit from lutein/zeaxanthin or omega-3 in the primary analysis. Secondary analyses supported **lutein/zeaxanthin in place of beta carotene**.
CHANGED PRACTICE	Produced the AREDS2 formula. Ten-year follow-up: lutein/zeaxanthin vs beta carotene HR 0.85 for late AMD; beta carotene nearly doubled lung-cancer risk.

EXAM TRAP The substitution came from secondary analyses. Omega-3 adds nothing; 25 mg zinc was as good as 80 mg.

GATHER1

2021 AND GATHER2 2023

Trial names, not abbreviations (pivotal trials of avacincaptad pegol).

STUDY SNAPSHOT

Avacincaptad pegol 2 mg (or 4 mg in GATHER1) monthly vs sham · 286 + 448 patients · Extrafoveal geographic atrophy · 12 months

QUESTION	Can a complement C5 inhibitor slow geographic atrophy?
ANSWER	GA growth slowed by **27.4% (2 mg) and 27.8% (4 mg)** in GATHER1 and by **14%** in GATHER2 (0.336 vs 0.392 mm/year).
CHANGED PRACTICE	Second approved treatment for geographic atrophy (FDA, August 2023).

EXAM TRAP Growth is measured on square-root-transformed area, so the percentages cannot be compared directly with OAKS and DERBY. It slows the lesion, not the vision loss. Neovascularisation 7% vs 4% sham in GATHER2.

NOW Not available in Europe: the EMA application was withdrawn in October 2024 over doubts about clinically meaningful visual benefit.

OAKS AND DERBY

2023

Trial names, not abbreviations (phase 3 trials of pegcetacoplan).

STUDY SNAPSHOT

Pegcetacoplan 15 mg monthly or every other month vs sham · 1,258 patients aged 60 or over · geographic atrophy · 24 months

QUESTION	Can a complement C3 inhibitor slow geographic atrophy?
ANSWER	GA growth slowed at 24 months by **22% and 18%** (OAKS) and **19% and 16%** (DERBY), monthly and every other month. **No difference in vision.**
CHANGED PRACTICE	First approved treatment for geographic atrophy (FDA, February 2023).

EXAM TRAP DERBY missed significance at 12 months (12% and 11%). Anatomy, not vision. New wet AMD was more common: 11–13% with monthly dosing vs 2–4% with sham.

NOW Not approved by the EMA or the UK MHRA, which judged the benefit not clinically meaningful. Occlusive retinal vasculitis has been reported since launch.

REFERENCES

1. Treatment of Age-Related Macular Degeneration With Photodynamic Therapy (TAP) Study Group. Photodynamic therapy of subfoveal choroidal neovascularization in age-related macular degeneration with verteporfin: one-year results of 2 randomized clinical trials--TAP report. Arch Ophthalmol. 1999;117(10):1329-45. PMID: 10532441.

2. Verteporfin In Photodynamic Therapy Study Group. Verteporfin therapy of subfoveal choroidal neovascularization in age-related macular degeneration: two-year results of a randomized clinical trial including lesions with occult with no classic choroidal

neovascularization--verteporfin in photodynamic therapy report 2. Am J Ophthalmol. 2001;131(5):541-60. doi:10.1016/s0002-9394(01)00967-9. PMID: 11336929.

3. Gragoudas ES, Adamis AP, Cunningham ET, Feinsod M, Guyer DR. Pegaptanib for neovascular age-related macular degeneration. N Engl J Med. 2004;351(27):2805-16. doi:10.1056/NEJMoa042760. PMID: 15625332.

4. Heier JS, Boyer DS, Ciulla TA, Ferrone PJ, Jumper JM, Gentile RC, et al. Ranibizumab combined with verteporfin photodynamic therapy in neovascular age-related macular degeneration: year 1 results of the FOCUS Study. Arch Ophthalmol. 2006;124(11):1532-42. doi:10.1001/archopht.124.11.1532. PMID: 17101999.

5. Brown DM, Kaiser PK, Michels M, Soubrane G, Heier JS, Kim RY, et al. Ranibizumab versus verteporfin for neovascular age-related macular degeneration. N Engl J Med. 2006;355(14):1432-44. doi:10.1056/NEJMoa062655. PMID: 17021319.

6. Rosenfeld PJ, Brown DM, Heier JS, Boyer DS, Kaiser PK, Chung CY, et al. Ranibizumab for neovascular age-related macular degeneration. N Engl J Med. 2006;355(14):1419-31. doi:10.1056/NEJMoa054481. PMID: 17021318.

7. Regillo CD, Brown DM, Abraham P, Yue H, Ianchulev T, Schneider S, et al. Randomized, double-masked, sham-controlled trial of ranibizumab for neovascular age-related macular degeneration: PIER Study year 1. Am J Ophthalmol. 2008;145(2):239-248. doi:10.1016/j.ajo.2007.10.004. PMID: 18222192.

8. Schmidt-Erfurth U, Eldem B, Guymer R, Korobelnik JF, Schlingemann RO, Axer-Siegel R, et al. Efficacy and safety of monthly versus quarterly ranibizumab treatment in neovascular age-related macular degeneration: the EXCITE study. Ophthalmology. 2011;118(5):831-9. doi:10.1016/j.ophtha.2010.09.004. PMID: 21146229.

9. Lalwani GA, Rosenfeld PJ, Fung AE, Dubovy SR, Michels S, Feuer W, et al. A variable-dosing regimen with intravitreal ranibizumab for neovascular age-related macular degeneration: year 2 of the PrONTO Study. Am J Ophthalmol. 2009;148(1):43-58.e1. doi:10.1016/j.ajo.2009.01.024. PMID: 19376495.

10. Holz FG, Amoaku W, Donate J, Guymer RH, Kellner U, Schlingemann RO, et al. Safety and efficacy of a flexible dosing regimen of ranibizumab in neovascular age-related macular degeneration: the SUSTAIN study. Ophthalmology. 2011;118(4):663-71. doi:10.1016/j.ophtha.2010.12.019. PMID: 21459217.

11. Martin DF, Maguire MG, Ying GS, Grunwald JE, Fine SL, Jaffe GJ. Ranibizumab and bevacizumab for neovascular age-related macular degeneration. N Engl J Med. 2011;364(20):1897-908. doi:10.1056/NEJMoa1102673. PMID: 21526923.

12. Martin DF, Maguire MG, Fine SL, Ying GS, Jaffe GJ, Grunwald JE, et al. Ranibizumab and bevacizumab for treatment of neovascular age-related macular degeneration: two-year results. Ophthalmology. 2012;119(7):1388-98. doi:10.1016/j.ophtha.2012.03.053. PMID: 22555112.

13. Koh A, Lee WK, Chen LJ, Chen SJ, Hashad Y, Kim H, et al. EVEREST study: efficacy and safety of verteporfin photodynamic therapy in combination with ranibizumab or alone versus ranibizumab monotherapy in patients with symptomatic macular polypoidal choroidal vasculopathy. Retina. 2012;32(8):1453-64. doi:10.1097/IAE.0b013e31824f91e8. PMID: 22426346.

14. Chakravarthy U, Harding SP, Rogers CA, Downes SM, Lotery AJ, Culliford LA, et al. Alternative treatments to inhibit VEGF in age-related choroidal neovascularisation: 2-year findings of the IVAN randomised controlled trial. Lancet. 2013;382(9900):1258-67. doi:10.1016/S0140-6736(13)61501-9. PMID: 23870813.

15. Heier JS, Brown DM, Chong V, Korobelnik JF, Kaiser PK, Nguyen QD, et al. Intravitreal aflibercept (VEGF trap-eye) in wet age-related macular degeneration. Ophthalmology. 2012;119(12):2537-48. doi:10.1016/j.ophtha.2012.09.006. PMID: 23084240.

16. Dugel PU, Koh A, Ogura Y, Jaffe GJ, Schmidt-Erfurth U, Brown DM, et al. HAWK and HARRIER: Phase 3, Multicenter, Randomized, Double-Masked Trials of Brolucizumab for Neovascular Age-Related Macular Degeneration. Ophthalmology. 2020;127(1):72-84. doi:10.1016/j.ophtha.2019.04.017. PMID: 30986442.

17. Heier JS, Khanani AM, Quezada Ruiz C, Basu K, Ferrone PJ, Brittain C, et al. Efficacy, durability, and safety of intravitreal faricimab up to every 16 weeks for neovascular age-related macular degeneration (TENAYA and LUCERNE): two randomised, double-masked, phase 3, non-inferiority trials. Lancet. 2022;399(10326):729-740. doi:10.1016/S0140-6736(22)00010-1. PMID: 35085502.

18. Age-Related Eye Disease Study Research Group. A randomized, placebo-controlled, clinical trial of high-dose supplementation with vitamins C and E, beta carotene, and zinc for age-related macular degeneration and vision loss: AREDS report no. 8. Arch Ophthalmol. 2001;119(10):1417-36. doi:10.1001/archopht.119.10.1417. PMID: 11594942.

19. Age-Related Eye Disease Study 2 Research Group. Lutein + zeaxanthin and omega-3 fatty acids for age-related macular degeneration: the Age-Related Eye Disease Study 2 (AREDS2) randomized clinical trial. JAMA. 2013;309(19):2005-15. doi:10.1001/jama.2013.4997. PMID: 23644932.

20. Jaffe GJ, Westby K, Csaky KG, Monés J, Pearlman JA, Patel SS, et al. C5 Inhibitor Avacincaptad Pegol for Geographic Atrophy Due to Age-Related Macular Degeneration: A Randomized Pivotal Phase 2/3 Trial. Ophthalmology. 2021;128(4):576-586. doi:10.1016/j.ophtha.2020.08.027. PMID: 32882310.

21. Khanani AM, Patel SS, Staurenghi G, Tadayoni R, Danzig CJ, Eichenbaum DA, et al. Efficacy and safety of avacincaptad pegol in patients with geographic atrophy (GATHER2): 12-month results from a randomised, double-masked, phase 3 trial. Lancet. 2023;402(10411):1449-1458. doi:10.1016/S0140-6736(23)01583-0. PMID: 37696275.

22. Heier JS, Lad EM, Holz FG, Rosenfeld PJ, Guymer RH, Boyer D, et al. Pegcetacoplan for the treatment of geographic atrophy secondary to age-related macular degeneration (OAKS and DERBY): two multicentre, randomised, double-masked, sham-controlled, phase 3 trials. Lancet. 2023;402(10411):1434-1448. doi:10.1016/S0140-6736(23)01520-9. PMID: 37865470.

2

RETINAL VEIN OCCLUSION

RVO trials answer three questions: does medical therapy work for macular oedema, does laser work, and when should neovascularisation be lasered. Laser lasted longer in BRVO than in CRVO; for oedema in either, anti-VEGF has replaced it.

STORY LINE CRVO: CVOS (grid laser fails; PRP only once new vessels appear) → SCORE CRVO (triamcinolone beats observation) → CRUISE, COPERNICUS, GALILEO (anti-VEGF beats sham) and GENEVA (dexamethasone implant) → CRYSTAL (ischaemia need not deter treatment) → COMRADE (ranibizumab beats one implant). BRVO: BVOS (grid laser works; scatter only for new vessels) → SCORE BRVO (steroid no better than laser) → BRAVO, VIBRANT, BRIGHTER (anti-VEGF beats laser).

CENTRAL RETINAL VEIN OCCLUSION

CVOS

1995

Central Vein Occlusion Study

STUDY SNAPSHOT

Two RCTs within a cohort of 728 eyes: grid laser vs observation for oedema (155 eyes); prophylactic PRP vs observation for ischaemic CRVO (181 eyes) · up to 3 years

QUESTION Does laser help CRVO oedema, and should ischaemic CRVO get PRP before new vessels appear?

ANSWER Grid laser **reduced oedema but did not improve acuity**. Prophylactic PRP did not significantly prevent iris/angle neovascularisation.

CHANGED PRACTICE	Laser for CRVO is for established new vessels only. Ischaemic CRVO = 10 disc areas or more of non-perfusion.

EXAM TRAP Poor presenting acuity predicts rubeosis: 44% of eyes worse than 6/60 developed it (16% of all eyes). Anatomical improvement without functional gain.

NOW Anti-VEGF or dexamethasone implant for oedema; PRP once neovascularisation develops.

SCORE CRVO

2009

Standard Care vs COrticosteroid for REtinal Vein Occlusion (CRVO trial)

STUDY SNAPSHOT

Intravitreal triamcinolone 1 mg or 4 mg vs observation · 271 participants · 12 months

QUESTION	Does steroid help CRVO macular oedema?
ANSWER	Yes: 15-letter gain in **27% (1 mg) and 26% (4 mg) vs 7%**.
CHANGED PRACTICE	First treatment shown to improve vision in CRVO oedema.

EXAM TRAP No dose-response: 1 mg did as much as 4 mg with fewer side effects.

NOW Displaced by anti-VEGF and the dexamethasone implant.

CRUISE

2010

Central Retinal Vein OcclUsIon Study: Evaluation of Efficacy and Safety

STUDY SNAPSHOT

Monthly ranibizumab 0.3 or 0.5 mg vs sham · 392 patients · CMT 250 µm or more · 6 months

QUESTION	Does anti-VEGF work in CRVO oedema?
ANSWER	**+12.7 and +14.9 letters vs +0.8** at 6 months; 15-letter gain 46% and 48% vs 17%.
CHANGED PRACTICE	Made ranibizumab first-line for CRVO oedema.

EXAM TRAP Six-month primary endpoint; the sham arm received ranibizumab thereafter.

GENEVA

2010

Global Evaluation of implaNtable dExamethasone in retinal Vein occlusion with macular edemA

STUDY SNAPSHOT

Dexamethasone implant 0.35 or 0.7 mg vs sham · 1,267 patients · CRVO and BRVO · 6 months

QUESTION	Can a single slow-release steroid implant treat RVO oedema?
ANSWER	Cumulative 15-letter gain over 6 months **41% (0.7 mg) and 40% vs 23%**; effect peaked at 60 days.
CHANGED PRACTICE	Licensed Ozurdex 0.7 mg for RVO oedema (both CRVO and BRVO).

EXAM TRAP Primary endpoint was time to 15-letter gain. Peak at day 60: 29% vs 9% (CRVO), 30% vs 13% (BRVO); no difference from sham by day 180, so retreatment is often needed earlier.

COPERNICUS

2012

COntrolled Phase 3 Evaluation of Repeated iNtravitreal administration of VEGF Trap-Eye In Central retinal vein occlusion: Utility and Safety

STUDY SNAPSHOT

Aflibercept 2 mg vs sham monthly to week 24, then PRN aflibercept in both arms · 189 patients · 1 year

QUESTION	Does aflibercept work in CRVO oedema?
ANSWER	15-letter gain **56.1% vs 12.3%** at week 24; at 1 year +16.2 vs +3.8 letters.
CHANGED PRACTICE	With GALILEO, the basis of aflibercept for CRVO.

EXAM TRAP The sham arm switched to aflibercept at week 24, so its 1-year figure is not a true sham.

GALILEO

2013/2014

General Assessment Limiting InfiLtration of Exudates in central retinal vein Occlusion with VEGF Trap-Eye

STUDY SNAPSHOT

Aflibercept 2 mg vs sham monthly to week 24; then PRN aflibercept in the aflibercept arm only · 177 patients · 1 year

QUESTION	Does aflibercept replicate COPERNICUS?
ANSWER	Yes: primary (week 24) 15-letter gain **60.2% vs 22.1%**; at week 52 +16.9 vs +3.8 letters.
CHANGED PRACTICE	Confirmed COPERNICUS.

EXAM TRAP Unlike COPERNICUS, the **sham arm stayed on sham to week 48**; the two trials' year-one sham arms are not comparable.

COMRADE

2016

Trial name, not an abbreviation. COMRADE-B (BRVO)(2018) and COMRADE-C (CRVO)(2016): efficacy and safety of ranibizumab intravitreal injections versus dexamethasone intravitreal implant.

STUDY SNAPSHOT

Ranibizumab monthly then PRN vs a single dexamethasone implant · COMRADE-C 243 and COMRADE-B 244 patients · 6 months

QUESTION	Ranibizumab or Ozurdex for RVO oedema?
ANSWER	CRVO: **+12.9 vs +3.0 letters** (mean over months 1–6); BRVO **+17.3 vs +9.2** at month 6; 4.5 injections vs one implant.
CHANGED PRACTICE	Supported anti-VEGF as first choice for RVO oedema.

EXAM TRAP The implant was not allowed to be repeated within 6 months, so its effect had waned by month 3. In the extension the CRVO difference was no longer significant.

CRYSTAL

2018

Trial name, not an abbreviation.

STUDY SNAPSHOT

Ranibizumab 0.5 mg, stabilisation-driven · 357 patients · open-label single-arm · 24 months

QUESTION	Does macular ischaemia or delay reduce the benefit of anti-VEGF in CRVO?
ANSWER	Mean gain **+12.1 letters**; similar with and without ischaemia (**11.1 vs 12.9**); larger when treated within 3 months (13.2 vs 10.5).
CHANGED PRACTICE	Ischaemia need not deter anti-VEGF treatment.

EXAM TRAP Single-arm, **not an RCT**: the duration effect is an association, not proof that delay causes harm.

BRANCH RETINAL VEIN OCCLUSION

BVOS

1984

Branch Vein Occlusion Study

STUDY SNAPSHOT

Grid laser vs observation (macular oedema, acuity 6/12 or worse); scatter laser vs observation (neovascularisation) · 3 years

QUESTION	Does laser help BRVO oedema and neovascularisation?
ANSWER	Grid laser: **65% vs 37%** gained 2 lines (+1.33 vs +0.23 lines). Scatter laser once new vessels appear cut vitreous haemorrhage from about **60% to 30%**.
CHANGED PRACTICE	Grid laser became standard for BRVO oedema for 25 years.

EXAM TRAP Do **not** give scatter laser prophylactically: only about 40% of ischaemic eyes (>5 disc diameters of non-perfusion) develop new vessels, and 60% of those bleed. Grid laser: 100 µm, 0.1 s, after waiting about 3 months.

NOW Anti-VEGF has replaced grid laser for oedema; sector laser remains for new vessels.

SCORE BRVO

2009

Standard Care vs COrticosteroid for REtinal Vein Occlusion (BRVO trial)

STUDY SNAPSHOT

Grid laser vs intravitreal triamcinolone 1 mg or 4 mg · 411 participants · 12 months

QUESTION	Is steroid better than laser in BRVO oedema?
ANSWER	No: 15-letter gain **29% (laser), 26% and 27%**, no significant difference.
CHANGED PRACTICE	Kept grid laser as standard care until anti-VEGF.

EXAM TRAP The mirror image of SCORE CRVO: steroid beat observation in CRVO but not laser in BRVO, and added cataract and raised IOP.

BRAVO

2010

BRAnch Retinal Vein Occlusion: Evaluation of Efficacy and Safety

STUDY SNAPSHOT

Monthly ranibizumab 0.3 or 0.5 mg vs sham, rescue laser from 3 months · 397 patients · 12 months

QUESTION	Does anti-VEGF work in BRVO oedema?
ANSWER	At 6 months (primary) **+16.6 and +18.3 vs +7.3 letters** (15-letter gain 55% and 61% vs 29%); at 12 months +16.4 and +18.3 vs +12.1.
CHANGED PRACTICE	Made ranibizumab first-line for BRVO oedema.

EXAM TRAP The sham arm gained 12.1 letters by 12 months because rescue laser and PRN ranibizumab were allowed.

VIBRANT

2015

Trial name, not an abbreviation. Full title: Study of the efficacy, safety and tolerability of intravitreal VEGF Trap-Eye (aflibercept) in macular oedema secondary to branch retinal vein occlusion.

STUDY SNAPSHOT

Aflibercept 4-weekly vs grid laser · 183 patients · 24 weeks

QUESTION	Is aflibercept better than laser in BRVO oedema?
ANSWER	Yes: 15-letter gain **52.7% vs 26.7%**; **+17.0 vs +6.9 letters**.
CHANGED PRACTICE	Aflibercept's evidence for BRVO.

EXAM TRAP Comparator was laser, not sham or another anti-VEGF.

BRIGHTER

2017

Trial name, not an abbreviation.

STUDY SNAPSHOT

Ranibizumab vs ranibizumab + laser vs laser · BRVO macular oedema · 24 months

QUESTION	Does adding laser to ranibizumab save injections?
ANSWER	Ranibizumab beat laser; **adding laser did not reduce injection numbers**.
CHANGED PRACTICE	Ended combination laser as an injection-saving strategy.

EXAM TRAP Laser added work without benefit.

REFERENCES

1. The Central Vein Occlusion Study Group. Evaluation of grid pattern photocoagulation for macular edema in central vein occlusion. The Central Vein Occlusion Study Group M report. Ophthalmology. 1995;102(10):1425-33. doi:10.1016/s0161-6420(95)30849-4. PMID: 9097788.

2. The Central Vein Occlusion Study Group. A randomized clinical trial of early panretinal photocoagulation for ischemic central vein occlusion. The Central Vein Occlusion Study Group N report. Ophthalmology. 1995;102(10):1434-44. PMID: 9097789.

3. Ip MS, Scott IU, VanVeldhuisen PC, Oden NL, Blodi BA, Fisher M, et al. A randomized trial comparing the efficacy and safety of intravitreal triamcinolone with observation to treat vision loss associated with macular edema secondary to central retinal vein occlusion: the Standard Care vs Corticosteroid for Retinal Vein Occlusion (SCORE) study report 5. Arch Ophthalmol. 2009;127(9):1101-14. doi:10.1001/archophthalmol.2009.234. PMID: 19752419.

4. Brown DM, Campochiaro PA, Singh RP, Li Z, Gray S, Saroj N, et al. Ranibizumab for macular edema following central retinal vein occlusion: six-month primary end point results of a phase III study. Ophthalmology. 2010;117(6):1124-1133.e1. doi:10.1016/j.ophtha.2010.02.022. PMID: 20381871.

5. Haller JA, Bandello F, Belfort R, Blumenkranz MS, Gillies M, Heier J, et al. Randomized, sham-controlled trial of dexamethasone intravitreal implant in patients with macular edema due to retinal vein occlusion. Ophthalmology. 2010;117(6):1134-1146.e3. doi:10.1016/j.ophtha.2010.03.032. PMID: 20417567.

6. Boyer D, Heier J, Brown DM, Clark WL, Vitti R, Berliner AJ, et al. Vascular endothelial growth factor Trap-Eye for macular edema secondary to central retinal vein occlusion: six-month results of the phase 3 COPERNICUS study. Ophthalmology. 2012;119(5):1024-32. doi:10.1016/j.ophtha.2012.01.042. PMID: 22440275.

7. Brown DM, Heier JS, Clark WL, Boyer DS, Vitti R, Berliner AJ, et al. Intravitreal aflibercept injection for macular edema secondary to central retinal vein occlusion: 1-year results from the phase 3 COPERNICUS study. Am J Ophthalmol. 2013;155(3):429-437.e7. doi:10.1016/j.ajo.2012.09.026. PMID: 23218699.

8. Holz FG, Roider J, Ogura Y, Korobelnik JF, Simader C, Groetzbach G, et al. VEGF Trap-Eye for macular oedema secondary to central retinal vein occlusion: 6-month results of the phase III GALILEO study. Br J Ophthalmol. 2013;97(3):278-84. doi:10.1136/bjophthalmol-2012-301504. PMID: 23298885.

9. Korobelnik JF, Holz FG, Roider J, Ogura Y, Simader C, Schmidt-Erfurth U, et al. Intravitreal Aflibercept Injection for Macular Edema Resulting from Central Retinal Vein Occlusion: One-Year Results of the Phase 3 GALILEO Study. Ophthalmology. 2014;121(1):202-208. doi:10.1016/j.ophtha.2013.08.012. PMID: 24084497.

10. Hoerauf H, Feltgen N, Weiss C, Paulus EM, Schmitz-Valckenberg S, Pielen A, et al. Clinical Efficacy and Safety of Ranibizumab Versus Dexamethasone for Central Retinal Vein Occlusion (COMRADE C): A European Label Study. Am J Ophthalmol. 2016;169:258-267. doi:10.1016/j.ajo.2016.04.020. PMID: 27163237.

11. Hattenbach LO, Feltgen N, Bertelmann T, Schmitz-Valckenberg S, Berk H, Eter N, et al. Head-to-head comparison of ranibizumab PRN versus single-dose dexamethasone for branch retinal vein occlusion (COMRADE-B). Acta Ophthalmol. 2018;96(1):e10-e18. doi:10.1111/aos.13381. PMID: 28251811.

12. Larsen M, Waldstein SM, Boscia F, Gerding H, Monés J, Tadayoni R, et al. Individualized Ranibizumab Regimen Driven by Stabilization Criteria for Central Retinal Vein Occlusion: Twelve-Month Results of the CRYSTAL Study. Ophthalmology. 2016;123(5):1101-11. doi:10.1016/j.ophtha.2016.01.011. PMID: 26896124.

13. Larsen M, Waldstein SM, Priglinger S, Hykin P, Barnes E, Gekkieva M, et al. Sustained Benefits from Ranibizumab for Central Retinal Vein Occlusion with Macular Edema: 24-Month Results of the CRYSTAL Study. Ophthalmol Retina. 2018;2(2):134-142. doi:10.1016/j.oret.2017.05.016. PMID: 31047340.

14. The Branch Vein Occlusion Study Group. Argon laser photocoagulation for macular edema in branch vein occlusion. Am J Ophthalmol. 1984;98(3):271-82. doi:10.1016/0002-9394(84)90316-7. PMID: 6383055.

15. Scott IU, Ip MS, VanVeldhuisen PC, Oden NL, Blodi BA, Fisher M, et al. A randomized trial comparing the efficacy and safety of intravitreal triamcinolone with standard care to treat vision loss associated with macular Edema secondary to branch retinal vein occlusion: the Standard Care vs Corticosteroid for Retinal Vein Occlusion (SCORE) study report 6. Arch Ophthalmol. 2009;127(9):1115-28. doi:10.1001/archophthalmol.2009.233. PMID: 19752420.

16. Campochiaro PA, Heier JS, Feiner L, Gray S, Saroj N, Rundle AC, et al. Ranibizumab for macular edema following branch retinal vein occlusion: six-month primary end point results of a phase III study. Ophthalmology. 2010;117(6):1102-1112.e1. doi:10.1016/j.ophtha.2010.02.021. PMID: 20398941.

17. Campochiaro PA, Clark WL, Boyer DS, Heier JS, Brown DM, Vitti R, et al. Intravitreal aflibercept for macular edema following branch retinal vein occlusion: the 24-week results of the VIBRANT study. Ophthalmology. 2015;122(3):538-44. doi:10.1016/j.ophtha.2014.08.031. PMID: 25315663.

18. Tadayoni R, Waldstein SM, Boscia F, Gerding H, Gekkieva M, Barnes E, et al. Sustained Benefits of Ranibizumab with or without Laser in Branch Retinal Vein Occlusion: 24-Month Results of the BRIGHTER Study. Ophthalmology. 2017;124(12):1778-1787. doi:10.1016/j.ophtha.2017.06.027. PMID: 28807635.

3

MYOPIC CNV AND CENTRAL SEROUS CHORIORETINOPATHY

Four short trials, each with one quotable comparison.

STORY LINE Myopic CNV: RADIANCE (ranibizumab beats PDT) → MYRROR (aflibercept beats sham). Chronic CSCR: PLACE (half-dose PDT beats micropulse) → VICI (eplerenone does not work).

RADIANCE

2014

Trial name, not an abbreviation. Full title: A randomized controlled study of ranibizumab in patients with choroidal neovascularization secondary to pathologic myopia.

STUDY SNAPSHOT

Ranibizumab (two retreatment strategies) vs verteporfin PDT · 277 patients · primary endpoint months 1–3, followed to 12 months

QUESTION	Is anti-VEGF better than PDT for myopic CNV?
ANSWER	Yes: **+10.5 and +10.6 vs +2.2 letters** (mean over months 1–3).
CHANGED PRACTICE	Made ranibizumab first-line for myopic CNV.

EXAM TRAP PDT patients could switch to ranibizumab from month 3, so later comparisons are not randomised.

MYRROR

2015

Trial name, not an abbreviation. Full title: Intravitreal aflibercept injection in patients with myopic choroidal neovascularization.

STUDY SNAPSHOT

Aflibercept vs sham (3:1) · 122 patients · Asian centres · primary endpoint week 24

QUESTION	Does aflibercept work in myopic CNV?
ANSWER	Yes: **+12.1 vs −2.0 letters** at week 24, with a median of **2 injections** during the first 12 weeks.
CHANGED PRACTICE	Added aflibercept as an option for myopic CNV.

EXAM TRAP Sham eyes received aflibercept after week 24, so the week-48 figures (+13.5 vs +3.9) are not a sham comparison.

PLACE

2018

***P**hotodynamic therapy versus micropulse **LA**ser treatment in **C**hronic central s**E**rous chorioretinopathy*

STUDY SNAPSHOT

Half-dose PDT vs high-density subthreshold micropulse laser · 179 patients · chronic CSCR · open-label

QUESTION	Which laser treatment clears fluid in chronic CSCR?
ANSWER	Half-dose PDT: no fluid in **51.2% vs 13.8%** at 6–8 weeks and **67.2% vs 28.8%** at 7–8 months.
CHANGED PRACTICE	Made half-dose PDT the reference treatment for chronic CSCR.

EXAM TRAP Final visit was 7–8 months, not 12. Applies to chronic, not acute, CSCR.

VICI

2020

Trial name, not an abbreviation. Full title: Eplerenone for chronic central serous chorioretinopathy in patients with active, previously untreated disease for more than 4 months.

STUDY SNAPSHOT

Eplerenone vs placebo · 114 patients · chronic CSCR · 12 months

QUESTION	Does the mineralocorticoid antagonist everyone was prescribing work?
ANSWER	**No difference in acuity.**
CHANGED PRACTICE	The authors concluded eplerenone should not be used for chronic CSCR.

EXAM TRAP The endpoint was acuity.

NOW SPECTRA (2021) found half-dose PDT better than eplerenone.

REFERENCES

1. Wolf S, Balciuniene VJ, Laganovska G, Menchini U, Ohno-Matsui K, Sharma T, et al. RADIANCE: a randomized controlled study of ranibizumab in patients with choroidal neovascularization secondary to pathologic myopia. Ophthalmology. 2014;121(3):682-92.e2. doi:10.1016/j.ophtha.2013.10.023. PMID: 24326106.
2. Ikuno Y, Ohno-Matsui K, Wong TY, Korobelnik JF, Vitti R, Li T, et al. Intravitreal Aflibercept Injection in Patients with Myopic Choroidal Neovascularization: The MYRROR Study. Ophthalmology. 2015;122(6):1220-7. doi:10.1016/j.ophtha.2015.01.025. PMID: 25745875.
3. van Dijk EHC, Fauser S, Breukink MB, Blanco-Garavito R, Groenewoud JMM, Keunen JEE, et al. Half-Dose Photodynamic Therapy versus High-Density Subthreshold Micropulse Laser Treatment in Patients with Chronic Central Serous Chorioretinopathy: The PLACE Trial. Ophthalmology. 2018;125(10):1547-1555. doi:10.1016/j.ophtha.2018.04.021. PMID: 29776672.
4. Lotery A, Sivaprasad S, O'Connell A, Harris RA, Culliford L, Ellis L, et al. Eplerenone for chronic central serous chorioretinopathy in patients with active, previously untreated disease for more than 4 months (VICI): a randomised, double-blind, placebo-controlled trial. Lancet. 2020;395(10220):294-303. doi:10.1016/S0140-6736(19)32981-2. PMID: 31982075.

4

DIABETIC RETINOPATHY AND DIABETIC MACULAR OEDEMA

The deepest evidence base in ophthalmology, in two stories: laser and systemic control first, then intravitreal drugs displacing laser for centre-involving oedema and challenging PRP itself. The DRCR.net protocols have their own chapter next.

STORY LINE Laser era: DRS (PRP halves severe visual loss) → DRVS (early vitrectomy for vitreous haemorrhage) → ETDRS (focal laser; defer PRP). Systemic: DCCT (type 1) and UKPDS (type 2). Drug era for DMO: READ-1 (proof of concept), READ-2, BOLT, RESOLVE, DA VINCI, RESTORE, RISE/RIDE, VIVID/VISTA (anti-VEGF beats laser). Steroids: FAME, MEAD. PDR: CLARITY (aflibercept vs PRP) → PANORAMA (NPDR). For Protocols A, B, I, T, V, S and AB, see Chapter 5.

DRS

1976

Diabetic Retinopathy Study

STUDY SNAPSHOT

One eye immediate PRP (argon or xenon), fellow eye observed · 1,758 patients · PDR or bilateral severe NPDR

QUESTION	Does PRP prevent blindness in advanced diabetic retinopathy?
ANSWER	Yes: severe visual loss cut by **50% or more** (about **16% vs 6%** at 2 years).

CHANGED PRACTICE	Founded laser treatment of diabetic retinopathy and defined the **high-risk characteristics** that still mean treat now.

EXAM TRAP High-risk PDR: NVD of ¼–⅓ disc area or more(with or without haemorrhage), or any NVD with vitreous or preretinal haemorrhage or NVE ≥ ½ disc area with vitreous/preretinal haemorrhage. Untreated severe NPDR: half develop PDR within 15 months.

DRVS

1985

Diabetic Retinopathy Vitrectomy Study

STUDY SNAPSHOT

Early vitrectomy (within days of entry, 1–6 months after the bleed) vs deferral for 1 year · 616 eyes · severe vitreous haemorrhage, acuity 5/200 or worse · 2 years

QUESTION	Should severe diabetic vitreous haemorrhage be operated on early?
ANSWER	20/40 or better in **25% vs 15%**; in type 1 diabetes **36% vs 12%**.
CHANGED PRACTICE	Early vitrectomy for type 1 diabetics with severe haemorrhage.

EXAM TRAP No benefit in type 2 (16% vs 18%). More eyes had no light perception after early surgery: significantly so up to 18 months, 25% vs 19% (not significant) at 2 years. Pre-dates endolaser.

NOW Surgery is now offered much earlier, with anti-VEGF as an alternative (Protocol AB).

ETDRS

1985/1991

Early Treatment Diabetic Retinopathy Study

STUDY SNAPSHOT

Early vs deferred PRP; focal laser for macular oedema; aspirin vs placebo · 3,711 patients

QUESTION	When to give PRP, and does laser help macular oedema?
ANSWER	Focal laser cut moderate visual loss from **24% to 12%** at 3 years in CSMO. Early PRP gave only a small benefit.
CHANGED PRACTICE	Defined **CSMO** and the rule: defer PRP in mild-moderate NPDR, consider it in severe NPDR, give it for high-risk PDR. Aspirin neither helped nor harmed.

EXAM TRAP CSMO: thickening within 500 µm of the centre; exudate within 500 µm with adjacent thickening; or thickening of 1 disc area or more within 1 disc diameter of the centre.

NOW OCT-defined centre-involved DMO and anti-VEGF have replaced CSMO and focal laser for centre-involving disease.

DCCT

1993

Diabetes Control and Complications Trial

STUDY SNAPSHOT

Intensive (HbA1c about 7.2%) vs conventional control · 1,441 type 1 patients · 6.5 years

QUESTION	Does tight glucose control prevent retinopathy?
ANSWER	Incidence cut by **76%**, progression by **54%**.
CHANGED PRACTICE	Made HbA1c an ophthalmic outcome.

EXAM TRAP Rapid tightening can cause early worsening; the benefit persisted for years afterwards (EDIC, 'metabolic memory').

UKPDS

1998

United Kingdom Prospective Diabetes Study

STUDY SNAPSHOT

Intensive vs conventional glucose control; tight (<150/85) vs less tight (<180/105) blood pressure · 5,102 type 2 patients

QUESTION	Do glucose and blood pressure control protect the retina in type 2 diabetes?
ANSWER	Glucose (HbA1c about 7%): microvascular disease **−25%** (retinopathy progression −21%, PRP −29%). Blood pressure (mean 144/82): microvascular **−37%**, diabetes deaths −32%, progression −34%, 3-line loss −47%.
CHANGED PRACTICE	Made blood-pressure control part of diabetic eye care.

EXAM TRAP The blood-pressure effect was at least as large as the glucose effect; the two were not compared directly.

READ-1

2006

Ranibizumab for Edema of the mAcula in Diabetes (pilot)

STUDY SNAPSHOT

Non-randomised pilot · 10 patients · chronic DMO · ranibizumab 0.5 mg × 5 · 7 months

QUESTION	Is VEGF a target in diabetic macular oedema?
ANSWER	Foveal thickness **503 → 257 µm** (85% of the excess); acuity **+12.3 letters** (20/80 → 20/40).
CHANGED PRACTICE	First proof that blocking VEGF dries diabetic macular oedema; led directly to READ-2.

EXAM TRAP Ten patients and no control arm: proof of concept, not evidence of benefit.

READ-2

2009

Ranibizumab for Edema of the mAcula in Diabetes, phase 2

STUDY SNAPSHOT

Ranibizumab vs laser vs both · 126 patients · DMO · 6 months

QUESTION	Does combining laser with ranibizumab help?
ANSWER	**+7.2** (ranibizumab), **+3.8** (combination), **−0.4** (laser) letters.
CHANGED PRACTICE	Early signal that laser adds nothing to anti-VEGF.

EXAM TRAP Only six months.

BOLT

2010/2012

Bevacizumab Or Laser Therapy in the management of diabetic macular oedema

STUDY SNAPSHOT

Bevacizumab vs macular laser · 80 eyes · DMO · 2 years

QUESTION	Is bevacizumab effective in DMO?
ANSWER	**+8.6 letters vs −0.5** at 24 months.
CHANGED PRACTICE	Gave widely used bevacizumab a randomised basis in DMO.

EXAM TRAP Three numbers, do not mix them. Primary outcome: final acuity **64.4 vs 54.8 letters** (20/50 vs 20/80). Mean change: +8.6 vs −0.5. Median gain: 9 vs 2.5. Also single centre, and every eye had already had laser, so the laser arm was re-treating laser failures.

RESOLVE

2010

Trial name, not an abbreviation. Full title: Safety and efficacy of ranibizumab in diabetic macular edema with center involvement.

STUDY SNAPSHOT

Ranibizumab 0.3 or 0.5 mg vs sham, monthly ×3 then as needed · 151 patients · DMO · 12 months

QUESTION	Does ranibizumab work in DMO?
ANSWER	**+10.3 vs −1.4 letters**.
CHANGED PRACTICE	Early phase II proof of anti-VEGF in DMO.

EXAM TRAP Doses were not separated, so it shows efficacy, not the best dose.

DA VINCI

2011

DME And VEGF Trap-Eye: INvestigation of Clinical Impact

STUDY SNAPSHOT

Four aflibercept regimens vs laser · 221 patients · DMO · phase II · 24 weeks

QUESTION	Which aflibercept schedules should go to phase III?
ANSWER	All regimens gained **+8.5 to +11.4 letters vs +2.5** with laser.
CHANGED PRACTICE	Led to the VIVID/VISTA regimens.

EXAM TRAP Phase II: differences between regimens are descriptive only.

RESTORE

2011

Trial name, not an abbreviation. Full title: Ranibizumab monotherapy or combined with laser versus laser monotherapy for diabetic macular edema.

STUDY SNAPSHOT

Ranibizumab + sham laser vs ranibizumab + laser vs sham injection + laser · 345 patients · DMO · 12 months

QUESTION	Is ranibizumab better than laser, and does adding laser help?
ANSWER	**+6.1 and +5.9 vs +0.8 letters**.
CHANGED PRACTICE	Established ranibizumab, with or without laser, over laser alone for DMO.

EXAM TRAP Adding laser added nothing; injection needs fell over the 3-year extension.

FAME

2012

Fluocinolone Acetonide in diabetic Macular Edema

STUDY SNAPSHOT

Fluocinolone implant 0.2 or 0.5 µg/day vs sham (2:2:1) · 956 patients · DMO previously treated with laser · 3 years

QUESTION	Does a 3-year steroid implant help persistent DMO?
ANSWER	15-letter gain **28.7% and 27.8% vs 18.9%**; in chronic DMO 34.0% vs 13.4%.
CHANGED PRACTICE	Licensed Iluvien, used for chronic DMO not responding to other therapy, mainly in pseudophakic eyes.

EXAM TRAP Cataract in most phakic eyes and glaucoma surgery in a minority; the comparator was sham, not anti-VEGF.

RISE AND RIDE

2012

Trial names, not abbreviations. Full title of both: A study of Ranibizumab Injection in subjects with clinically significant macular edema with center involvement secondary to Diabetes mellitus.

STUDY SNAPSHOT

Monthly ranibizumab 0.3 or 0.5 mg vs sham, rescue laser from 3 months · 377 and 382 patients · DMO · 24 months

QUESTION	The paired phase III trials of ranibizumab in DMO.
ANSWER	15-letter gain: RISE **44.8% and 39.2% vs 18.1%**; RIDE **33.6% and 45.7% vs 12.3%**.
CHANGED PRACTICE	Basis of FDA approval of ranibizumab 0.3 mg for DMO.

EXAM TRAP The dose ranking reversed between the two trials, so there is no consistent dose effect.

MEAD

2014

Macular Edema: Assessment of implantable Dexamethasone in diabetes

STUDY SNAPSHOT

Dexamethasone implant 0.7 or 0.35 mg vs sham · 1,048 patients · DMO · 3 years

QUESTION	Does the dexamethasone implant help DMO?
ANSWER	15-letter gain **22.2% and 18.4% vs 12.0%**; mean gain over 3 years **+6.5 vs +1.7 letters in pseudophakic eyes** (+3.5 vs +2.0 overall).
CHANGED PRACTICE	The implant is used mainly in pseudophakic eyes.

EXAM TRAP Phakic eyes lose the gain to cataract until it is removed (cataract in 68%); 0.6% needed trabeculectomy. Only 43% of the sham arm finished, which flatters sham.

VIVID AND VISTA

2014/2015

Trial names, not abbreviations. VIVID-DME: Intravitreal aflibercept injection in vision impairment due to DME. VISTA-DME: Study of intravitreal administration of VEGF Trap-Eye in patients with DME.

STUDY SNAPSHOT

Aflibercept 2 mg monthly or 8-weekly (after 5 monthly doses) vs laser · 872 patients · DMO · 52 weeks (primary), 100 weeks

QUESTION	The paired phase III trials of aflibercept in DMO.
ANSWER	At 52 weeks: VISTA **+12.5 and +10.7 vs +0.2**; VIVID **+10.5 and +10.7 vs +1.2** letters.
CHANGED PRACTICE	Licensed 8-weekly aflibercept for DMO.

EXAM TRAP +11.5, +11.1 and +0.9 are VISTA's 100-week figures. Laser is the only comparator; drug ranking comes from Protocol T.

CLARITY

2017

Trial name, not an abbreviation. Full title: Clinical efficacy and mechanistic evaluation of aflibercept for proliferative diabetic retinopathy.

STUDY SNAPSHOT

Aflibercept 2 mg at weeks 0, 4 and 8, then as needed every 4 weeks, vs PRP · 232 patients · active PDR, untreated or after previous PRP, no macular oedema · UK phase 2b non-inferiority · 52 weeks

QUESTION	Is aflibercept at least as good as PRP for vision in proliferative diabetic retinopathy?
ANSWER	Yes, non-inferior and then superior: **+3.9 letters** (95% CI 2.3–5.6) at 52 weeks, with about **4 injections** in the year (3 loading plus a mean of 1.4).
CHANGED PRACTICE	First trial to show anti-VEGF superior to PRP on acuity in PDR; supported aflibercept as an alternative to PRP.

EXAM TRAP A milder population than Protocol S: only 23% high-risk PDR, 47% previously lasered, none with macular oedema. One year only, at higher cost. Visual fields were a secondary outcome.

PANORAMA

2021

Trial name, not an abbreviation.

STUDY SNAPSHOT

Aflibercept 16-weekly or 8-weekly vs sham · 402 eyes · moderately severe to severe NPDR without centre-involved DMO

QUESTION	Does anti-VEGF reverse the retinopathy itself?
ANSWER	2-step improvement **58% vs 6%** at 24 weeks and **65–80% vs 15%** at 52 weeks; fewer vision-threatening complications.
CHANGED PRACTICE	Showed anti-VEGF can regress retinopathy severity, not just treat oedema.

EXAM TRAP The endpoint is severity steps, not acuity.

NOW Protocol W: preventive aflibercept gave no acuity benefit at 4 years, so routine prophylaxis is not recommended.

REFERENCES

1. The Diabetic Retinopathy Study Research Group. Preliminary report on effects of photocoagulation therapy. Am J Ophthalmol. 1976;81(4):383-96. doi:10.1016/0002-9394(76)90292-0. PMID: 944535.
2. The Diabetic Retinopathy Vitrectomy Study Research Group. Early vitrectomy for severe vitreous hemorrhage in diabetic retinopathy. Two-year results of a randomized trial. Diabetic Retinopathy Vitrectomy Study report 2. Arch Ophthalmol. 1985;103(11):1644-52. PMID: 2865943.
3. Early Treatment Diabetic Retinopathy Study Research Group. Photocoagulation for diabetic macular edema. Early Treatment Diabetic Retinopathy Study report number 1. Arch Ophthalmol. 1985;103(12):1796-806. PMID: 2866759.
4. Early Treatment Diabetic Retinopathy Study Research Group. Early photocoagulation for diabetic retinopathy. ETDRS report number 9. Ophthalmology. 1991;98(5 Suppl):766-85. PMID: 2062512.
5. Diabetes Control and Complications Trial Research Group; Nathan DM, Genuth S, Lachin J, Cleary P, Crofford O, Davis M, et al. The effect of intensive treatment of diabetes on the development and progression of long-term complications in insulin-dependent diabetes mellitus. N Engl J Med. 1993;329(14):977-86. doi:10.1056/NEJM199309303291401. PMID: 8366922.
6. UK Prospective Diabetes Study (UKPDS) Group. Intensive blood-glucose control with sulphonylureas or insulin compared with conventional treatment and risk of complications in patients with type 2 diabetes (UKPDS 33). Lancet. 1998;352(9131):837-53. PMID: 9742976.

7. UK Prospective Diabetes Study Group. Tight blood pressure control and risk of macrovascular and microvascular complications in type 2 diabetes: UKPDS 38. BMJ. 1998;317(7160):703-13. PMID: 9732337.

8. Nguyen QD, Tatlipinar S, Shah SM, Haller JA, Quinlan E, Sung J, et al. Vascular endothelial growth factor is a critical stimulus for diabetic macular edema. Am J Ophthalmol. 2006;142(6):961-9. doi:10.1016/j.ajo.2006.06.068. PMID: 17046701.

9. Nguyen QD, Shah SM, Heier JS, Do DV, Lim J, Boyer D, et al. Primary End Point (Six Months) Results of the Ranibizumab for Edema of the mAcula in diabetes (READ-2) study. Ophthalmology. 2009;116(11):2175-81.e1. doi:10.1016/j.ophtha.2009.04.023. PMID: 19700194.

10. Michaelides M, Kaines A, Hamilton RD, Fraser-Bell S, Rajendram R, Quhill F, et al. A prospective randomized trial of intravitreal bevacizumab or laser therapy in the management of diabetic macular edema (BOLT study) 12-month data: report 2. Ophthalmology. 2010;117(6):1078-1086.e2. doi:10.1016/j.ophtha.2010.03.045. PMID: 20416952.

11. Rajendram R, Fraser-Bell S, Kaines A, Michaelides M, Hamilton RD, Esposti SD, et al. A 2-year prospective randomized controlled trial of intravitreal bevacizumab or laser therapy (BOLT) in the management of diabetic macular edema: 24-month data: report 3. Arch Ophthalmol. 2012;130(8):972-9. doi:10.1001/archophthalmol.2012.393. PMID: 22491395.

12. Massin P, Bandello F, Garweg JG, Hansen LL, Harding SP, Larsen M, et al. Safety and efficacy of ranibizumab in diabetic macular edema (RESOLVE Study): a 12-month, randomized, controlled, double-masked, multicenter phase II study. Diabetes Care. 2010;33(11):2399-405. doi:10.2337/dc10-0493. PMID: 20980427.

13. Do DV, Schmidt-Erfurth U, Gonzalez VH, Gordon CM, Tolentino M, Berliner AJ, et al. The DA VINCI Study: phase 2 primary results of VEGF Trap-Eye in patients with diabetic macular edema. Ophthalmology. 2011;118(9):1819-26. doi:10.1016/j.ophtha.2011.02.018. PMID: 21546089.

14. Mitchell P, Bandello F, Schmidt-Erfurth U, Lang GE, Massin P, Schlingemann RO, et al. The RESTORE study: ranibizumab monotherapy or combined with laser versus laser monotherapy for diabetic macular edema. Ophthalmology. 2011;118(4):615-25. doi:10.1016/j.ophtha.2011.01.031. PMID: 21459215.

15. Campochiaro PA, Brown DM, Pearson A, Chen S, Boyer D, Ruiz-Moreno J, et al. Sustained delivery fluocinolone acetonide vitreous inserts provide benefit for at least 3 years in patients with diabetic macular edema. Ophthalmology. 2012;119(10):2125-32. doi:10.1016/j.ophtha.2012.04.030. PMID: 22727177.

16. Nguyen QD, Brown DM, Marcus DM, Boyer DS, Patel S, Feiner L, et al. Ranibizumab for diabetic macular edema: results from 2 phase III randomized trials: RISE and RIDE. Ophthalmology. 2012;119(4):789-801. doi:10.1016/j.ophtha.2011.12.039. PMID: 22330964.

17. Boyer DS, Yoon YH, Belfort R, Bandello F, Maturi RK, Augustin AJ, et al. Three-year, randomized, sham-controlled trial of dexamethasone intravitreal implant in patients with diabetic macular edema. Ophthalmology. 2014;121(10):1904-14. doi:10.1016/j.ophtha.2014.04.024. PMID: 24907062.

18. Korobelnik JF, Do DV, Schmidt-Erfurth U, Boyer DS, Holz FG, Heier JS, et al. Intravitreal aflibercept for diabetic macular edema. Ophthalmology. 2014;121(11):2247-54. doi:10.1016/j.ophtha.2014.05.006. PMID: 25012934.

19. Sivaprasad S, Prevost AT, Vasconcelos JC, Riddell A, Murphy C, Kelly J, et al. Clinical efficacy of intravitreal aflibercept versus panretinal photocoagulation for best corrected visual acuity in patients with proliferative diabetic retinopathy at 52 weeks

(CLARITY): a multicentre, single-blinded, randomised, controlled, phase 2b, non-inferiority trial. Lancet. 2017;389(10085):2193-2203. doi:10.1016/S0140-6736(17)31193-5. PMID: 28494920.

20. Brown DM, Wykoff CC, Boyer D, Heier JS, Clark WL, Emanuelli A, et al. Evaluation of Intravitreal Aflibercept for the Treatment of Severe Nonproliferative Diabetic Retinopathy: Results From the PANORAMA Randomized Clinical Trial. JAMA Ophthalmol. 2021;139(9):946-955. doi:10.1001/jamaophthalmol.2021.2809. PMID: 34351414.

5

DRCR.NET PROTOCOLS

The DRCR Retina Network (DRCR.net until 2018) runs NEI-funded pragmatic trials in diabetic eye disease. Each protocol is named by a letter and answers one practical question, and examiners quote them by letter.

STORY LINE DMO: Protocol A (modified-ETDRS laser as the standard) → Protocol B (laser beats triamcinolone) → Protocol I (ranibizumab beats laser; prompt laser adds nothing) → Protocol T (aflibercept when vision is 20/50 or worse) → Protocol V (good vision can be observed). PDR: Protocol S (ranibizumab non-inferior to PRP) → Protocol AB (aflibercept or vitrectomy for vitreous haemorrhage).

DRCR.NET PROTOCOL A

2007

Diabetic Retinopathy Clinical Research Network (now the DRCR Retina Network), Protocol A

STUDY SNAPSHOT

Modified-ETDRS focal/grid laser vs mild macular grid · 323 eyes · DMO · 12 months

QUESTION	Can laser be made gentler without losing effect?
ANSWER	Modified-ETDRS laser **reduced OCT thickening more**; acuity differed only slightly.
CHANGED PRACTICE	Fixed modified-ETDRS laser as the comparator for later DRCR trials.

EXAM TRAP The primary outcome was anatomical (OCT), not acuity.

DRCR.NET PROTOCOL B

2008

Diabetic Retinopathy Clinical Research Network (now the DRCR Retina Network), Protocol B

STUDY SNAPSHOT

Intravitreal triamcinolone 1 or 4 mg vs focal/grid laser · 840 eyes · DMO · 2–3 years

QUESTION	Is triamcinolone better than laser for DMO?
ANSWER	No: 4 mg led at 4 months, groups were level at 1 year, and **laser was better at 2 years**.
CHANGED PRACTICE	Confirmed laser as standard before anti-VEGF; steroid kept for refractory cases.

EXAM TRAP Concerns triamcinolone, not the sustained-release implants tested in FAME and MEAD.

DRCR.NET PROTOCOL I

2010

Diabetic Retinopathy Clinical Research Network (now the DRCR Retina Network), Protocol I

STUDY SNAPSHOT

Sham + laser vs ranibizumab + prompt laser vs ranibizumab + deferred laser vs triamcinolone + laser · 854 eyes · centre-involved DMO

QUESTION	Ranibizumab or laser for centre-involved DMO, and does laser add anything?
ANSWER	Ranibizumab beat laser with or without triamcinolone; **prompt laser added nothing**.
CHANGED PRACTICE	Made anti-VEGF first-line for centre-involved DMO.

EXAM TRAP In pseudophakic eyes triamcinolone + laser did about as well as ranibizumab: the origin of steroid's niche in pseudophakic DMO.

DRCR.NET PROTOCOL T

2015/2016

Diabetic Retinopathy Clinical Research Network (now the DRCR Retina Network), Protocol T

STUDY SNAPSHOT

Aflibercept vs bevacizumab vs ranibizumab 0.3 mg · 660 participants · centre-involved DMO · 2 years

QUESTION	Which anti-VEGF for DMO?
ANSWER	With acuity **20/50 (about 6/15) or worse**, aflibercept was best at 1 year; at 20/40 or better, no real difference.
CHANGED PRACTICE	Aflibercept first for poor-vision DMO; any agent when vision is good.

EXAM TRAP At 2 years aflibercept still beat bevacizumab (+18.1 vs +13.3 letters) but no longer ranibizumab. The cut-off is 20/50, not 6/12.

DRCR.NET PROTOCOL S

2015/2018

Diabetic Retinopathy Clinical Research Network (now the DRCR Retina Network), Protocol S

STUDY SNAPSHOT

Ranibizumab 0.5 mg vs PRP · 394 eyes (305 participants) · PDR · 5 years

QUESTION	Can anti-VEGF replace PRP for proliferative diabetic retinopathy?
ANSWER	Acuity **non-inferior** at 2 years and equal at 5 (**+3.1 vs +3.0 letters**); **less field loss and less DMO** with ranibizumab.
CHANGED PRACTICE	Made anti-VEGF an alternative to PRP, after a mean of 19.2 injections over 5 years.

EXAM TRAP A non-inferiority trial, not an acuity advantage. Patients lost to follow-up on anti-VEGF did worse; only 66% completed 5 years.

DRCR.NET PROTOCOL V

2019

Diabetic Retinopathy Clinical Research Network (now the DRCR Retina Network), Protocol V

STUDY SNAPSHOT

Aflibercept vs laser vs observation, with aflibercept on vision loss · 702 eyes · centre-involved DMO with acuity 20/25 or better · 2 years

QUESTION	Must centre-involved DMO with good vision be treated?
ANSWER	**No significant difference** in vision loss at 2 years.
CHANGED PRACTICE	Observation is reasonable, provided follow-up is reliable.

EXAM TRAP Aflibercept was started in 25% of the laser and 34% of the observation group: 'observe' means observe and treat on worsening.

DRCR.NET PROTOCOL AB

2020

Diabetic Retinopathy Clinical Research Network (now the DRCR Retina Network), Protocol AB

STUDY SNAPSHOT

Aflibercept vs vitrectomy with PRP · vitreous haemorrhage from PDR · 24 weeks

QUESTION	Inject or operate for diabetic vitreous haemorrhage?
ANSWER	**No significant difference** in mean acuity over 24 weeks.
CHANGED PRACTICE	Either route is acceptable.

EXAM TRAP Vision recovered faster after vitrectomy.

REFERENCES

1. Fong DS, Strauber SF, Aiello LP, Beck RW, Callanan DG, Danis RP, et al. Comparison of the modified Early Treatment Diabetic Retinopathy Study and mild macular grid laser photocoagulation strategies for diabetic macular edema. Arch Ophthalmol. 2007;125(4):469-80. doi:10.1001/archopht.125.4.469. PMID: 17420366.

2. Diabetic Retinopathy Clinical Research Network. A randomized trial comparing intravitreal triamcinolone acetonide and focal/grid photocoagulation for diabetic macular edema. Ophthalmology. 2008;115(9):1447-9, 1449.e1-10. doi:10.1016/j.ophtha.2008.06.015. PMID: 18662829.

3. Elman MJ, Aiello LP, Beck RW, Bressler NM, Bressler SB, Edwards AR, et al. Randomized trial evaluating ranibizumab plus prompt or deferred laser or triamcinolone plus prompt laser for diabetic macular edema. Ophthalmology. 2010;117(6):1064-1077.e35. doi:10.1016/j.ophtha.2010.02.031. PMID: 20427088.

4. Wells JA, Glassman AR, Ayala AR, Jampol LM, Aiello LP, Antoszyk AN, et al. Aflibercept, bevacizumab, or ranibizumab for diabetic macular edema. N Engl J Med. 2015;372(13):1193-203. doi:10.1056/NEJMoa1414264. PMID: 25692915.

5. Wells JA, Glassman AR, Ayala AR, Jampol LM, Bressler NM, Bressler SB, et al. Aflibercept, Bevacizumab, or Ranibizumab for Diabetic Macular Edema: Two-Year Results from a Comparative Effectiveness Randomized Clinical Trial. Ophthalmology. 2016;123(6):1351-9. doi:10.1016/j.ophtha.2016.02.022. PMID: 26935357.

6. Gross JG, Glassman AR, Jampol LM, Inusah S, Aiello LP, Antoszyk AN, et al. Panretinal Photocoagulation vs Intravitreous Ranibizumab for Proliferative Diabetic Retinopathy: A Randomized Clinical Trial. JAMA. 2015;314(20):2137-2146. doi:10.1001/jama.2015.15217. PMID: 26565927.

7. Gross JG, Glassman AR, Liu D, Sun JK, Antoszyk AN, Baker CW, et al. Five-Year Outcomes of Panretinal Photocoagulation vs Intravitreous Ranibizumab for Proliferative Diabetic Retinopathy: A Randomized Clinical Trial. JAMA Ophthalmol. 2018;136(10):1138-1148. doi:10.1001/jamaophthalmol.2018.3255. PMID: 30043039.

8. Baker CW, Glassman AR, Beaulieu WT, Antoszyk AN, Browning DJ, Chalam KV, et al. Effect of Initial Management With Aflibercept vs Laser Photocoagulation vs Observation on Vision Loss Among Patients With Diabetic Macular Edema Involving the Center of the Macula and Good Visual Acuity: A Randomized Clinical Trial. JAMA. 2019;321(19):1880-1894. doi:10.1001/jama.2019.5790. PMID: 31037289.

9. Antoszyk AN, Glassman AR, Beaulieu WT, Jampol LM, Jhaveri CD, Punjabi OS, et al. Effect of Intravitreous Aflibercept vs Vitrectomy With Panretinal Photocoagulation on Visual Acuity in Patients With Vitreous Hemorrhage From Proliferative Diabetic Retinopathy: A Randomized Clinical Trial. JAMA. 2020;324(23):2383-2395. doi:10.1001/jama.2020.23027. PMID: 33320223.

6

GLAUCOMA

Every glaucoma trial asks one question: if you lower the pressure, does the disease change course? Read them as a ladder, each lowering the threshold at which we intervene.

STORY LINE Does lowering IOP help? EMGT (early glaucoma), UKGTS (placebo-controlled), CNTGS (normal-tension), OHTS (ocular hypertension) → How low? AGIS → How to start? CIGTS (drops vs surgery), LiGHT (SLT first) → Which operation? TVT and PTVT (tube vs trabeculectomy), ABC (Ahmed vs Baerveldt) → Angle closure: EAGLE (clear lens extraction), ZAP (prophylactic iridotomy).

CNTGS

1998

Collaborative Normal-Tension Glaucoma Study

STUDY SNAPSHOT

30% IOP reduction vs no treatment · 145 patients · normal-tension glaucoma · about 5 years

QUESTION	Is there anything to treat when pressure is already normal?
ANSWER	Progression **12% vs 35%** after censoring cataract; the intention-to-treat difference was **not significant**.
CHANGED PRACTICE	A 30% reduction is the standard target in progressing NTG.

EXAM TRAP **65% of untreated eyes did not progress** over 5 years, so not every NTG patient needs treatment at diagnosis. Women (especially with migraine) and eyes with disc haemorrhage progressed more.

AGIS

2000

Advanced Glaucoma Intervention Study

STUDY SNAPSHOT

ALT-first vs trabeculectomy-first sequences · 591 patients (789 eyes) · advanced glaucoma uncontrolled on drops

QUESTION	How low should IOP be in advanced glaucoma?
ANSWER	Eyes **below 18 mmHg at every visit (mean 12.3)** had almost no field change; early mean IOP **above 17.5 vs below 14 mmHg** meant more field loss (1.9 units at 7 years). Black patients did better with **ATT**, white patients with **TAT**.
CHANGED PRACTICE	Set the low-teens target for advanced disease.

EXAM TRAP The pressure result (AGIS 7) is observational, pooling both arms; the race-by-sequence result (AGIS 4) is the randomised comparison. The study target was below 18 mmHg, not 12. Trabeculectomy raised cataract risk (RR 1.78).

CIGTS

2001

Collaborative Initial Glaucoma Treatment Study

STUDY SNAPSHOT

Stepped medication vs trabeculectomy first · 607 patients · newly diagnosed open-angle glaucoma

QUESTION	Drops or surgery first?
ANSWER	Surgery lowered IOP more (48% vs 35% reduction; 14–15 vs 17–18 mmHg) but **field outcomes were similar**.
CHANGED PRACTICE	Drops first for most new glaucoma.

EXAM TRAP Secondary analysis: eyes with worse baseline fields did better with surgery first. Cataract was commoner after trabeculectomy.

EMGT

2002

Early Manifest Glaucoma Trial

STUDY SNAPSHOT

Betaxolol + ALT vs no treatment · 255 patients · newly diagnosed early glaucoma, IOP below 30 · median 6 years

QUESTION	Does lowering IOP slow early glaucoma?
ANSWER	Progression **45% vs 62%**, with a mean IOP fall of 5.1 mmHg (25%).
CHANGED PRACTICE	Proved treatment slows progression; **each 1 mmHg lower is about 10% less risk**.

EXAM TRAP Treatment slows progression; it does not stop it.

OHTS

2002

Ocular Hypertension Treatment Study

STUDY SNAPSHOT

Topical drops vs observation · 1,636 participants · ocular hypertension (IOP 24–32 in one eye) · 5 years

QUESTION	Does treating ocular hypertension prevent glaucoma?
ANSWER	Conversion **4.4% vs 9.5%** with a 22.5% IOP reduction.
CHANGED PRACTICE	Treatment roughly halves conversion. Showed **thin central corneal thickness** is a risk factor, the basis of risk calculators.

EXAM TRAP Most untreated patients never convert; the question is whom to treat, not whether treatment works.

A B C

2011

Ahmed Baerveldt Comparison Study

STUDY SNAPSHOT

Ahmed vs Baerveldt · 276 patients · refractory glaucoma · 1 year

QUESTION	Which drainage implant?
ANSWER	Baerveldt lower IOP (**13.2 vs 15.4 mmHg**) but more serious complications (**34% vs 20%**).
CHANGED PRACTICE	Baerveldt for lower pressure, Ahmed for safety.

EXAM TRAP One-year data; at 5 years the Ahmed failed more from high IOP,Baerveldt from hypotony + serious complications.

T V T

2012 (FIVE-YEAR RESULTS)

Tube Versus Trabeculectomy Study

STUDY SNAPSHOT

Baerveldt tube vs trabeculectomy with MMC · 212 eyes · previous trabeculectomy and/or cataract surgery · 5 years

QUESTION	Tube or trabeculectomy in a previously operated eye?
ANSWER	Failure **29.8% (tube) vs 46.9% (trabeculectomy)**; reoperation 9% vs 29%.
CHANGED PRACTICE	Tubes became the preferred operation after previous surgery.

EXAM TRAP IOP and medication use were similar at 5 years; the difference is durability. Crude failure proportions (50% vs 33%) are also quoted.

UKGTS

2015

United Kingdom Glaucoma Treatment Study

STUDY SNAPSHOT

Latanoprost vs placebo · 516 patients · open-angle glaucoma · 2 years

QUESTION	Does a single drop protect the field against placebo?
ANSWER	Field deterioration **15.2% vs 25.6%** with an IOP fall of only 3.8 vs 0.9 mmHg.
CHANGED PRACTICE	First placebo-controlled proof that a drop preserves the field.

EXAM TRAP Baseline IOP was near normal (about 20 mmHg): even small reductions count.

EAGLE

2016

Effectiveness in Angle-closure Glaucoma of Lens Extraction

STUDY SNAPSHOT

Clear lens extraction vs laser iridotomy · 419 patients aged 50 or over, no cataract · PAC with IOP 30 or more, or PACG · 3 years

QUESTION	Lens or iridotomy first in angle closure?
ANSWER	No further glaucoma treatment needed in **61% vs 21%**; IOP 16.6 vs 17.9 mmHg; better quality of life.
CHANGED PRACTICE	Clear lens extraction became a first-line option; cost-effective (about £14,284 per QALY).

EXAM TRAP Excluded advanced glaucoma, previous acute attacks and symptomatic cataract.

PTVT

2018

Primary Tube Versus Trabeculectomy Study

STUDY SNAPSHOT

Baerveldt tube vs trabeculectomy with MMC · 242 patients · no previous surgery · 1 year

QUESTION	Tube or trabeculectomy in an unoperated eye?
ANSWER	Failure **17.3% (tube) vs 7.9% (trabeculectomy)**; trabeculectomy also gave lower IOP (12.4 vs 13.8 mmHg) on fewer drops (0.9 vs 2.1).
CHANGED PRACTICE	Trabeculectomy remains the first operation in unoperated eyes.

EXAM TRAP Previous surgery, not the device, explains the opposite TVT result. Serious complications were commoner after trabeculectomy (7% vs 1%).

NOW At 5 years failure (42% vs 35%) and reoperation (18.0% vs 10.4%) no longer differed significantly; trabeculectomy eyes needed fewer drops.

ZAP

2019

Zhongshan Angle Closure Prevention trial

STUDY SNAPSHOT

Iridotomy in one eye, fellow eye control · 889 primary angle-closure suspects · China · 6 years

QUESTION	Should all angle-closure suspects have prophylactic iridotomy?
ANSWER	Angle closure in **19 treated vs 36 untreated** eyes: a **47% risk reduction**, but rare overall (**NNT 44**).
CHANGED PRACTICE	Prophylactic iridotomy for all suspects is not justified.

EXAM TRAP The treatment works; the absolute risk is too low to treat everyone.

LIGHT

2019

Laser in Glaucoma and Ocular Hypertension Trial

STUDY SNAPSHOT

Selective laser trabeculoplasty vs drops first · 718 patients · newly diagnosed OAG or OHT · 3 years

QUESTION	Can SLT replace drops as first-line?
ANSWER	**74% drop-free** at 3 years; quality of life equal; 11 trabeculectomies with drops, none after SLT.
CHANGED PRACTICE	SLT became a first-line option.

EXAM TRAP Excluded eyes unsuitable for SLT (uveitis, poor angle view).

NOW At 6 years 69.8% of SLT eyes were at target without drops or surgery, with less progression (19.6% vs 26.8%).

REFERENCES

1. Collaborative Normal-Tension Glaucoma Study Group. Comparison of glaucomatous progression between untreated patients with normal-tension glaucoma and patients with therapeutically reduced intraocular pressures. Am J Ophthalmol. 1998;126(4):487-97. doi:10.1016/s0002-9394(98)00223-2. PMID: 9780093.
2. Collaborative Normal-Tension Glaucoma Study Group. The effectiveness of intraocular pressure reduction in the treatment of normal-tension glaucoma. Am J Ophthalmol. 1998;126(4):498-505. doi:10.1016/s0002-9394(98)00272-4. PMID: 9780094.
3. The AGIS Investigators. The Advanced Glaucoma Intervention Study (AGIS): 7. The relationship between control of intraocular pressure and visual field deterioration. Am J Ophthalmol. 2000;130(4):429-40. doi:10.1016/s0002-9394(00)00538-9. PMID: 11024415.
4. The AGIS Investigators. The Advanced Glaucoma Intervention Study (AGIS): 4. Comparison of treatment outcomes within race. Seven-year results. Ophthalmology. 1998;105(7):1146-64. doi:10.1016/s0161-6420(98)97013-0. PMID: 9663215.
5. Lichter PR, Musch DC, Gillespie BW, Guire KE, Janz NK, Wren PA, et al. Interim clinical outcomes in the Collaborative Initial Glaucoma Treatment Study comparing initial treatment randomized to medications or surgery. Ophthalmology. 2001;108(11):1943-53. doi:10.1016/s0161-6420(01)00873-9. PMID: 11713061.
6. Heijl A, Leske MC, Bengtsson B, Hyman L, Bengtsson B, Hussein M. Reduction of intraocular pressure and glaucoma progression: results from the Early Manifest Glaucoma Trial. Arch Ophthalmol. 2002;120(10):1268-79. doi:10.1001/archopht.120.10.1268. PMID: 12365904.

7. Kass MA, Heuer DK, Higginbotham EJ, Johnson CA, Keltner JL, Miller JP, et al. The Ocular Hypertension Treatment Study: a randomized trial determines that topical ocular hypotensive medication delays or prevents the onset of primary open-angle glaucoma. Arch Ophthalmol. 2002;120(6):701-13; discussion 829-30. doi:10.1001/archopht.120.6.701. PMID: 12049574.

8. Budenz DL, Barton K, Feuer WJ, Schiffman J, Costa VP, Godfrey DG, et al. Treatment outcomes in the Ahmed Baerveldt Comparison Study after 1 year of follow-up. Ophthalmology. 2011;118(3):443-52. doi:10.1016/j.ophtha.2010.07.016. PMID: 20932583.

9. Gedde SJ, Schiffman JC, Feuer WJ, Herndon LW, Brandt JD, Budenz DL. Treatment outcomes in the Tube Versus Trabeculectomy (TVT) study after five years of follow-up. Am J Ophthalmol. 2012;153(5):789-803.e2. doi:10.1016/j.ajo.2011.10.026. PMID: 22245458.

10. Garway-Heath DF, Crabb DP, Bunce C, Lascaratos G, Amalfitano F, Anand N, et al. Latanoprost for open-angle glaucoma (UKGTS): a randomised, multicentre, placebo-controlled trial. Lancet. 2015;385(9975):1295-304. doi:10.1016/S0140-6736(14)62111-5. PMID: 25533656.

11. Azuara-Blanco A, Burr J, Ramsay C, Cooper D, Foster PJ, Friedman DS, et al. Effectiveness of early lens extraction for the treatment of primary angle-closure glaucoma (EAGLE): a randomised controlled trial. Lancet. 2016;388(10052):1389-1397. doi:10.1016/S0140-6736(16)30956-4. PMID: 27707497.

12. Gedde SJ, Feuer WJ, Shi W, Lim KS, Barton K, Goyal S, et al. Treatment Outcomes in the Primary Tube Versus Trabeculectomy Study after 1 Year of Follow-up. Ophthalmology. 2018;125(5):650-663. doi:10.1016/j.ophtha.2018.02.003. PMID: 29477688.

13. Gedde SJ, Feuer WJ, Lim KS, Barton K, Goyal S, Ahmed II, et al. Treatment Outcomes in the Primary Tube Versus Trabeculectomy Study after 5 Years of Follow-up. Ophthalmology. 2022;129(12):1344-1356. doi:10.1016/j.ophtha.2022.07.003. PMID: 35835337.

14. He M, Jiang Y, Huang S, Chang DS, Munoz B, Aung T, et al. Laser peripheral iridotomy for the prevention of angle closure: a single-centre, randomised controlled trial. Lancet. 2019;393(10181):1609-1618. doi:10.1016/S0140-6736(18)32607-2. PMID: 30878226.

15. Gazzard G, Konstantakopoulou E, Garway-Heath D, Garg A, Vickerstaff V, Hunter R, et al. Selective laser trabeculoplasty versus eye drops for first-line treatment of ocular hypertension and glaucoma (LiGHT): a multicentre randomised controlled trial. Lancet. 2019;393(10180):1505-1516. doi:10.1016/S0140-6736(18)32213-X. PMID: 30862377.

7

CATARACT SURGERY

Little randomised evidence lies behind routine cataract practice. What we quote about safety comes from two large ESCRS trials and one national audit.

STORY LINE ESCRS (intracameral cefuroxime) → UK CND-EPR (benchmark complication rates) → PREMED (preventing macular oedema: NSAID plus steroid drops; triamcinolone in diabetics).

ESCRS

2006/2007

European Society of Cataract and Refractive Surgeons (Endophthalmitis Study)

STUDY SNAPSHOT

Intracameral cefuroxime ± topical levofloxacin (2×2 factorial) · 16,603 patients · Europe

QUESTION	Which prophylaxis prevents endophthalmitis after phaco?
ANSWER	Endophthalmitis **0.35%** with neither vs **0.05%** with both; omitting intracameral cefuroxime carried about **5 times** the risk.
CHANGED PRACTICE	Intracameral antibiotic became standard.

EXAM TRAP Clear corneal incision (5.9×), silicone IOL (3.1×) and complications (5.0×) were associations, not randomised comparisons.

UK CND-EPR

2009

United Kingdom Cataract National Dataset, Electronic Patient Record (multicentre audit)

STUDY SNAPSHOT

National electronic audit · 55,567 operations · observational

QUESTION	What are the real complication rates of cataract surgery?
ANSWER	Posterior capsule rupture and/or vitreous loss **1.92%**; CMO 1.6%; suprachoroidal haemorrhage 0.07%.
CHANGED PRACTICE	Set the benchmark rates quoted at consent.

EXAM TRAP Observational: describes what happens, not what works.

PREMED

2018

PREvention of Macular EDema after cataract surgery (ESCRS study)

STUDY SNAPSHOT

Non-diabetic: bromfenac vs dexamethasone vs both (914 patients) · diabetic: subconjunctival triamcinolone and/or intravitreal bevacizumab on top of both drops (213 patients) · 12 European centres · 12 weeks

QUESTION	How best to prevent macular oedema after cataract surgery?
ANSWER	Non-diabetic CSME within 12 weeks: **1.5%** combination vs 3.6% bromfenac vs 5.1% dexamethasone. Diabetic: **no CME** with subconjunctival triamcinolone; bevacizumab no effect.
CHANGED PRACTICE	Evidence for an NSAID plus steroid drop after routine cataract surgery, and subconjunctival triamcinolone in diabetics.

EXAM TRAP The diabetic arm tested injections, not drops: every diabetic patient also received both drops. Triamcinolone raised IOP more often.

REFERENCES

1. Endophthalmitis Study Group, European Society of Cataract & Refractive Surgeons. Prophylaxis of postoperative endophthalmitis following cataract surgery: results of the ESCRS multicenter study and identification of risk factors. J Cataract Refract Surg. 2007;33(6):978-88. doi:10.1016/j.jcrs.2007.02.032. PMID: 17531690.
2. Jaycock P, Johnston RL, Taylor H, Adams M, Tole DM, Galloway P, et al. The Cataract National Dataset electronic multi-centre audit of 55,567 operations: updating benchmark standards of care in the United Kingdom and internationally. Eye (Lond). 2009;23(1):38-49. doi:10.1038/sj.eye.6703015. PMID: 18034196.
3. Wielders LHP, Schouten JSAG, Winkens B, van den Biggelaar FJHM, Veldhuizen CA, Findl O, et al. European multicenter trial of the prevention of cystoid macular edema after cataract surgery in nondiabetics: ESCRS PREMED study report 1. J Cataract Refract Surg. 2018;44(4):429-439. doi:10.1016/j.jcrs.2018.01.029. PMID: 29778106.
4. Wielders LHP, Schouten JSAG, Winkens B, van den Biggelaar FJHM, Veldhuizen CA, Murta JCN, et al. Randomized controlled European multicenter trial on the prevention of cystoid macular edema after cataract surgery in diabetics: ESCRS PREMED Study Report 2. J Cataract Refract Surg. 2018;44(7):836-847. doi:10.1016/j.jcrs.2018.05.015. PMID: 30055692.

8

CORNEA AND OCULAR SURFACE

Across these trials one pattern holds: the drug that treats the surface is often not the drug that treats the stroma, and the host's immune response matters as much as the organism.

STORY LINE Herpes: HEDS stromal trials (steroid helps; oral antiviral adds nothing) → HEDS epithelial (oral antiviral adds nothing) → HEDS prevention (oral acyclovir prevents recurrence). Grafts: CCTS (HLA matching useless) → Cornea Donor Study (older donors fine). Keratitis: MUTT (natamycin for Fusarium), SCUT (steroid rarely helps). Dry eye: SANSIKA.

CCTS

1992

Collaborative Corneal Transplantation Studies

STUDY SNAPSHOT

HLA-matched donors (419 patients) and crossmatch study (37 patients) · high-risk grafts

QUESTION	Does tissue matching improve high-risk graft survival?
ANSWER	**HLA matching had no effect.** ABO-compatible grafts had fewer rejection failures (**16% vs 30%**).
CHANGED PRACTICE	HLA matching is not worthwhile.

EXAM TRAP The ABO finding was non-randomised and in high-risk grafts only; the Cornea Donor Study found no ABO effect in lower-risk grafts.

HEDS SKN

1994

Herpetic Eye Disease Study: Stromal Keratitis, Not on Steroid Trial

STUDY SNAPSHOT

Topical prednisolone (10-week taper) vs placebo, all on trifluridine · 106 patients (57 vs 49)

QUESTION	Does HSV stromal keratitis need steroid?
ANSWER	Yes: treatment failure **26% vs 73%** (68% lower risk), and faster resolution.
CHANGED PRACTICE	Topical steroid with antiviral cover for stromal keratitis.

EXAM TRAP Six-month outcome and recurrence were the same: steroid speeds recovery rather than changing the result.

HEDS SKS

1994

Herpetic Eye Disease Study: Stromal Keratitis, on Steroid Trial

STUDY SNAPSHOT

Oral acyclovir 400 mg five times daily vs placebo for 10 weeks, all on trifluridine + steroid · 104 patients

QUESTION	Does oral acyclovir add anything to topical treatment?
ANSWER	**No additional benefit.**
CHANGED PRACTICE	Oral acyclovir is not needed to treat established stromal keratitis.

EXAM TRAP Contrast with the prevention trial, where oral acyclovir did work.

HEDS IRT

1996

Herpetic Eye Disease Study: Iridocyclitis, Receiving Topical Steroids Trial

STUDY SNAPSHOT

Oral acyclovir vs placebo for 10 weeks, all on steroid · 50 patients

QUESTION	Does oral acyclovir help HSV iridocyclitis?
ANSWER	**Trend in favour**, not significant.
CHANGED PRACTICE	Suggestive, not conclusive.

EXAM TRAP Stopped early for slow recruitment and underpowered.

HEDS EKT

1997

Herpetic Eye Disease Study: Epithelial Keratitis Trial

STUDY SNAPSHOT

Oral acyclovir 400 mg five times daily for 21 days vs placebo, all on trifluridine · within 7 days of onset

QUESTION	Does oral acyclovir during epithelial keratitis prevent later stromal disease?
ANSWER	**No**: rates of stromal keratitis or iritis over the following year were the same.
CHANGED PRACTICE	Treat epithelial keratitis topically.

EXAM TRAP Save oral antiviral for prevention.

HEDS APT

1998

Herpetic Eye Disease Study: Acyclovir Prevention Trial

STUDY SNAPSHOT

Oral acyclovir 400 mg twice daily vs placebo · 703 patients · ocular HSV in the previous year, inactive 30 days or more · 12 months

QUESTION	Can recurrences be prevented?
ANSWER	Recurrence **19% vs 32%** (about 41% relative reduction); stromal recurrence 14% vs 28% in those with previous stromal disease.
CHANGED PRACTICE	Long-term oral acyclovir prophylaxis for recurrent HSV eye disease.

EXAM TRAP This is where oral antiviral earns its place.

CDS

2008

Cornea Donor Study

STUDY SNAPSHOT

Donors aged 10–75, masked allocation · about 1,100 patients · Fuchs dystrophy and pseudophakic oedema · 5 years

QUESTION	Are corneas from older donors safe?
ANSWER	**Five-year survival similar** for donors over and under 65; ABO compatibility made no difference.
CHANGED PRACTICE	Expanded the donor pool to age 75.

EXAM TRAP Endothelial cell loss was slightly greater with older donors (75% vs 69%).

NOW Ten-year survival was slightly lower with donors aged 66–75; endothelial keratoplasty has largely replaced PK for these conditions.

SCUT

2012

Steroids for Corneal Ulcers Trial

STUDY SNAPSHOT

Topical prednisolone 1% vs placebo after 48 hours of moxifloxacin · 500 patients · bacterial keratitis · 3 months

QUESTION	Does adjunctive steroid improve bacterial keratitis?
ANSWER	**No overall difference** in acuity, scar size or perforation.
CHANGED PRACTICE	No routine steroid for bacterial keratitis.

EXAM TRAP Possible benefit when baseline vision is counting fingers or worse; avoid in Nocardia.

MUTT 1

2013

Mycotic Ulcer Treatment Trial I

STUDY SNAPSHOT

Topical natamycin 5% vs voriconazole 1% · 323 patients · filamentous fungal keratitis · 3 months

QUESTION	Natamycin or voriconazole for fungal keratitis?
ANSWER	Natamycin: **better 3-month acuity and fewer perforations**.
CHANGED PRACTICE	Natamycin first-line for filamentous keratitis.

EXAM TRAP The benefit was driven by **Fusarium**.

NOW MUTT II: adding oral voriconazole gave no benefit.

SANSIKA

2016

Trial name, not an abbreviation.

STUDY SNAPSHOT

Ciclosporin 0.1% (Ikervis) vs vehicle · 246 patients · severe dry eye (Oxford grade 4) · 6 months

QUESTION	Does ciclosporin help severe dry eye?
ANSWER	Primary composite endpoint **missed** (28.6% vs 23.1%), but corneal staining improved more (p=0.037).
CHANGED PRACTICE	Ciclosporin (Ikervis) licensed for severe keratitis with dry eye.

EXAM TRAP The vehicle improved symptoms too; the benefit is on staining, not symptoms.

REFERENCES

1. The Collaborative Corneal Transplantation Studies Research Group. The collaborative corneal transplantation studies (CCTS). Effectiveness of histocompatibility matching in high-risk corneal transplantation. Arch Ophthalmol. 1992;110(10):1392-403. PMID: 1417537.

2. Barron BA, Gee L, Hauck WW, Kurinij N, Dawson CR, Jones DB, et al. Herpetic Eye Disease Study. A controlled trial of oral acyclovir for herpes simplex stromal keratitis. Ophthalmology. 1994;101(12):1871-82. doi:10.1016/s0161-6420(13)31155-5. PMID: 7997323.

3. Wilhelmus KR, Gee L, Hauck WW, Kurinij N, Dawson CR, Jones DB, et al. Herpetic Eye Disease Study. A controlled trial of topical corticosteroids for herpes simplex stromal keratitis. Ophthalmology. 1994;101(12):1883-95; discussion 1895-6. doi:10.1016/s0161-6420(94)31087-6. PMID: 7997324.

4. The Herpetic Eye Disease Study Group. A controlled trial of oral acyclovir for iridocyclitis caused by herpes simplex virus. Arch Ophthalmol. 1996;114(9):1065-72. doi:10.1001/archopht.1996.01100140267002. PMID: 8790090.

5. The Herpetic Eye Disease Study Group. A controlled trial of oral acyclovir for the prevention of stromal keratitis or iritis in patients with herpes simplex virus epithelial keratitis. The Epithelial Keratitis Trial. Arch Ophthalmol. 1997;115(6):703-12. doi:10.1001/archopht.1997.01100150705001. PMID: 9194719.

6. Herpetic Eye Disease Study Group. Acyclovir for the prevention of recurrent herpes simplex virus eye disease. N Engl J Med. 1998;339(5):300-6. doi:10.1056/NEJM199807303390503. PMID: 9696640.

7. Cornea Donor Study Investigator Group; Gal RL, Dontchev M, Beck RW, Mannis MJ, Holland EJ, Kollman C, et al. The effect of donor age on corneal transplantation outcome results of the cornea donor study. Ophthalmology. 2008;115(4):620-626.e6. doi:10.1016/j.ophtha.2008.01.003. PMID: 18387407.

8. Srinivasan M, Mascarenhas J, Rajaraman R, Ravindran M, Lalitha P, Glidden DV, et al. Corticosteroids for bacterial keratitis: the Steroids for Corneal Ulcers Trial (SCUT). Arch Ophthalmol. 2012;130(2):143-50. doi:10.1001/archophthalmol.2011.315. PMID: 21987582.

9. Prajna NV, Krishnan T, Mascarenhas J, Rajaraman R, Prajna L, Srinivasan M, et al. The mycotic ulcer treatment trial: a randomized trial comparing natamycin vs voriconazole. JAMA Ophthalmol. 2013;131(4):422-9. doi:10.1001/jamaophthalmol.2013.1497. PMID: 23710492.

10. Leonardi A, Van Setten G, Amrane M, Ismail D, Garrigue JS, Figueiredo FC, et al. Efficacy and safety of 0.1% cyclosporine A cationic emulsion in the treatment of severe dry eye disease: a multicenter randomized trial. Eur J Ophthalmol. 2016;26(4):287-96. doi:10.5301/ejo.5000779. PMID: 27055414.

9

UVEITIS

Uveitis trials are hard: the disease is heterogeneous and outcomes were long unstandardised. Two frameworks matter as much as any single trial.

STORY LINE Local steroid: HURON (dexamethasone implant) → POINT (intravitreal beats periocular for macular oedema) → MUST (implant vs systemic therapy). Systemic: FAST (methotrexate vs mycophenolate). Infection: Soheilian (intravitreal treatment for toxoplasmosis).

GUIDELINE: SUN and IUSG classification

Anatomical: anterior, intermediate, posterior, panuveitis (IUSG, adopted by SUN). Aetiological: infectious, non-infectious, masquerade.

Persistent: present for more than 3 months. Chronic: relapse within 3 months of stopping treatment. Recurrent: episodes separated by 3 months or more without treatment.

GUIDELINE: RCOphth/BSPAR JIA uveitis screening (2006)

Screen within 6 weeks of referral, then every 2 months for 6 months, then every 3–4 months.

Oligoarticular, psoriatic and enthesitis-related arthritis, onset under 11: onset under 3, screen 8 years; 3–4, 6 years; 5–8, 3 years; 9–10, 1 year.

Polyarticular ANA-positive, onset under 10: under 6, 5 years; 6–9, 2 years. Polyarticular ANA-negative, onset under 7: 5 years.

Symptomatic children (or suspected cataract or synechiae) within 1 week. After stopping methotrexate or other immunosuppression, return to 2-monthly screening for 6 months.

HURON

2011

Trial name, not an abbreviation.

STUDY SNAPSHOT

Dexamethasone implant 0.7 or 0.35 mg vs sham · 229 patients · non-infectious intermediate or posterior uveitis · 26 weeks

QUESTION	Does the dexamethasone implant control uveitis?
ANSWER	Vitreous haze cleared at week 8 in **47% (0.7 mg) vs 12%** (sham).
CHANGED PRACTICE	Ozurdex licensed for non-infectious posterior-segment uveitis.

EXAM TRAP IOP rise and cataract were not significantly different over 26 weeks.

SOHEILIAN

2011

STUDY SNAPSHOT

Intravitreal clindamycin + dexamethasone (1–3 injections) vs pyrimethamine, sulfadiazine and prednisolone · small RCT · ocular toxoplasmosis

QUESTION	Can intravitreal treatment replace six weeks of triple therapy?
ANSWER	**Equally effective** in reducing lesion size.
CHANGED PRACTICE	A reasonable alternative where adherence or blood monitoring is difficult.

EXAM TRAP Small trial.

MUST

2017

Multicenter Uveitis Steroid Treatment Trial

STUDY SNAPSHOT

Fluocinolone 0.59 mg implant (Retisert) vs systemic steroid + immunosuppression · 255 patients · 7 years

QUESTION	Implant or systemic therapy for chronic uveitis?
ANSWER	By 7 years acuity was **stable with systemic therapy and about 6 letters worse with the implant**.
CHANGED PRACTICE	Systemic therapy first for most patients.

EXAM TRAP Implant eyes had more cataract, raised IOP and glaucoma. Lower-dose inserts were not tested.

POINT

2019

PeriOcular vs INTravitreal corticosteroids for uveitic macular edema Trial

STUDY SNAPSHOT

Periocular triamcinolone vs intravitreal triamcinolone vs dexamethasone implant · uveitic macular oedema · 8 weeks primary

QUESTION	Which steroid route for uveitic macular oedema?
ANSWER	**Intravitreal routes reduced oedema more**: by 46% (implant) and 39% (triamcinolone) vs 23% (periocular) at 8 weeks, with about 5 letters more vision.
CHANGED PRACTICE	Intravitreal steroid preferred for uveitic macular oedema.

EXAM TRAP IOP of 24 mmHg or more was likelier with intravitreal treatment (significant for the implant, HR 2.5), with no difference between the two intravitreal options.

NOW MERIT (2023): for persistent oedema the implant beat intravitreal methotrexate and ranibizumab (thickness −35% vs −11% and −22% at 12 weeks).

FAST

2019

First-line Antimetabolites as Steroid-sparing Treatment uveitis trial

STUDY SNAPSHOT

Methotrexate 25 mg weekly vs mycophenolate 3 g daily · 216 patients · non-infectious uveitis · 6 months

QUESTION	Which first-line antimetabolite?
ANSWER	Treatment success **66.7% vs 57.1%**, not significantly different.
CHANGED PRACTICE	Either is acceptable; methotrexate is cheaper.

EXAM TRAP Methotrexate looked better in posterior and panuveitis in exploratory subgroups only.

REFERENCES

1. Jabs DA, Nussenblatt RB, Rosenbaum JT. Standardization of uveitis nomenclature for reporting clinical data. Results of the First International Workshop. Am J Ophthalmol. 2005;140(3):509-16. doi:10.1016/j.ajo.2005.03.057. PMID: 16196117.
2. Royal College of Ophthalmologists; British Society for Paediatric and Adolescent Rheumatology. Guidelines for screening for uveitis in juvenile idiopathic arthritis (JIA). London: Royal College of Ophthalmologists; 2006.
3. Lowder C, Belfort R, Lightman S, Foster CS, Robinson MR, Schiffman RM, et al. Dexamethasone intravitreal implant for noninfectious intermediate or posterior uveitis. Arch Ophthalmol. 2011;129(5):545-53. doi:10.1001/archophthalmol.2010.339. PMID: 21220619.
4. Soheilian M, Ramezani A, Azimzadeh A, Sadoughi MM, Dehghan MH, Shahghadami R, et al. Randomized trial of intravitreal clindamycin and dexamethasone versus pyrimethamine, sulfadiazine, and prednisolone in treatment of ocular toxoplasmosis. Ophthalmology. 2011;118(1):134-41. doi:10.1016/j.ophtha.2010.04.020. PMID: 20708269.
5. Kempen JH, Altaweel MM, Holbrook JT, Sugar EA, Thorne JE, Jabs DA. Association Between Long-Lasting Intravitreous Fluocinolone Acetonide Implant vs Systemic Anti-inflammatory Therapy and Visual Acuity at 7 Years Among Patients With Intermediate, Posterior, or Panuveitis. JAMA. 2017;317(19):1993-2005. doi:10.1001/jama.2017.5103. PMID: 28477440.
6. Thorne JE, Sugar EA, Holbrook JT, Burke AE, Altaweel MM, Vitale AT, et al. Periocular Triamcinolone vs. Intravitreal Triamcinolone vs. Intravitreal Dexamethasone Implant for the Treatment of Uveitic Macular Edema: The PeriOcular vs. INTravitreal corticosteroids for uveitic macular edema (POINT) Trial. Ophthalmology. 2019;126(2):283-295. doi:10.1016/j.ophtha.2018.08.021. PMID: 30269924.

7. Rathinam SR, Gonzales JA, Thundikandy R, Kanakath A, Murugan SB, Vedhanayaki R, et al. Effect of Corticosteroid-Sparing Treatment With Mycophenolate Mofetil vs Methotrexate on Inflammation in Patients With Uveitis: A Randomized Clinical Trial. JAMA. 2019;322(10):936-945. doi:10.1001/jama.2019.12618. PMID: 31503307.

10

PAEDIATRIC OPHTHALMOLOGY AND STRABISMUS

Retinopathy of prematurity is the spine of this chapter, followed by amblyopia and intermittent exotropia.

STORY LINE ROP: CRYO-ROP (treat threshold disease) → ETROP (treat type 1, earlier) → STOP-ROP (oxygen does not help) → BEAT-ROP and RAINBOW (anti-VEGF). Amblyopia: PEDIG (less treatment works). Exotropia: Newcastle (observe; score control).

CRYO-ROP

1988

Cryotherapy for Retinopathy of Prematurity

STUDY SNAPSHOT

Cryotherapy vs observation for threshold ROP · 291 infants

QUESTION	Does treating threshold ROP prevent blindness?
ANSWER	Unfavourable outcome **25.7% vs 47.4%** at 12 months (21.8% vs 43.0% at 3 months).
CHANGED PRACTICE	First proven treatment for ROP. Threshold: stage 3 in zone 1 or 2 over 5 contiguous or 8 total clock hours, with plus.

EXAM TRAP Cryotherapy, not laser; threshold was defined anatomically.

STOP-ROP

2000

Supplemental Therapeutic Oxygen for Prethreshold Retinopathy of Prematurity

STUDY SNAPSHOT

Oxygen saturation target 96–99% vs 89–94% · 649 infants with prethreshold ROP

QUESTION	Does extra oxygen stop ROP progressing?
ANSWER	Progression to threshold **48% (conventional) vs 41% (supplemental)**; adjusted OR 0.72 (0.52–1.01), not significant. Pneumonia or worse lung disease **13.2% vs 8.5%**.
CHANGED PRACTICE	Oxygen is not a treatment for established ROP, but it need not be restricted once prethreshold ROP is present.

EXAM TRAP Not the 'oxygen causes ROP' trial: extra oxygen given after prethreshold ROP did not make it worse. It says nothing about targets from birth (SUPPORT, BOOST II). The benefit without plus disease (46% vs 32%) was post hoc.

PEDIG ATS

2002

Pediatric Eye Disease Investigator Group, Amblyopia Treatment Studies

STUDY SNAPSHOT

Series of RCTs in children with amblyopia

QUESTION	How much treatment does amblyopia need?
ANSWER	Less than assumed: **atropine = patching** (moderate); **6 hours = full-time** (severe); **2 hours = 6 hours** (moderate).
CHANGED PRACTICE	Titrate occlusion to severity; start with glasses alone for at least 16 weeks.

EXAM TRAP Children aged 7–12 still respond, and those aged 13–17 do if not previously treated.

ETROP

2003/2004

Early Treatment for Retinopathy Of Prematurity

STUDY SNAPSHOT

Early laser for high-risk prethreshold ROP vs conventional management (treatment at threshold) · 401 infants

QUESTION	Should ROP be treated before threshold?
ANSWER	Unfavourable acuity **14.3% vs 19.8%**; unfavourable structure 9.0% vs 15.6%.
CHANGED PRACTICE	Defined **type 1 ROP: treat now**: zone 1 any stage with plus; zone 1 stage 3 without plus; zone 2 stage 2 or 3 with plus.

EXAM TRAP Type 2 (zone 1 stage 1–2 without plus; zone 2 stage 3 without plus): observe. Control eyes were treated at threshold, not just observed.

NEWCASTLE INTERMITTENT EXOTROPIA STUDY AND NEWCASTLE CONTROL SCORE

2004/2012

STUDY SNAPSHOT

Prospective cohort, not randomised · 460 children under 12 · 26 UK centres · 2 years

QUESTION	How should intermittent exotropia be managed?
ANSWER	**53% had no treatment**; 17% were treated for acuity only, 13% had non-surgical treatment for control, 17% had surgery. Only 0.5% became constant.
CHANGED PRACTICE	Active monitoring is reasonable. The **Newcastle Control Score** (home + clinic control): a score of 3 or more makes cure without surgery unlikely.

EXAM TRAP Observational: shows what happened, not what works best. Surgery improved angle and control, but 21% were overcorrected at 6 months.

BEAT-ROP

2011

Bevacizumab Eliminates the Angiogenic Threat of Retinopathy of Prematurity

STUDY SNAPSHOT

Intravitreal bevacizumab 0.625 mg vs laser · 150 infants · zone 1 or posterior zone 2 stage 3 with plus

QUESTION	Is bevacizumab better than laser for severe ROP?
ANSWER	Recurrence (infants) **6% vs 26%** overall; **6% vs 42% in zone 1** (P=0.003); no significant benefit in posterior zone 2.
CHANGED PRACTICE	Made anti-VEGF a first-line option for zone 1 stage 3+ and aggressive posterior ROP; laser stayed standard for most zone 2 disease. The peripheral retina keeps vascularising instead of being ablated. Bevacizumab is off-label; ranibizumab and aflibercept were later licensed for ROP.

EXAM TRAP Overall figures are per infant (6% vs 26%) or per eye (4% vs 22%): do not mix them. Too small to assess safety; recurrences after anti-VEGF come late, so follow-up must be longer.

RAINBOW

2019

RAnibizumab Compared With Laser Therapy for the Treatment of INfants BOrn Prematurely With Retinopathy of Prematurity

STUDY SNAPSHOT

Ranibizumab 0.2 or 0.1 mg vs laser · 225 infants under 1,500 g · 24 weeks

QUESTION	Is ranibizumab better than laser for ROP?
ANSWER	Success **80% (0.2 mg) vs 66%** with laser (p=0.051).
CHANGED PRACTICE	Ranibizumab licensed for ROP.

EXAM TRAP Narrowly missed significance; 24 weeks is too short to settle long-term systemic safety. Deaths were evenly distributed.

REFERENCES

1. Cryotherapy for Retinopathy of Prematurity Cooperative Group. Multicenter trial of cryotherapy for retinopathy of prematurity. Preliminary results. Arch Ophthalmol. 1988;106(4):471-9. doi:10.1001/archopht.1988.01060130517027. PMID: 2895630.
2. The STOP-ROP Multicenter Study Group. Supplemental Therapeutic Oxygen for Prethreshold Retinopathy Of Prematurity (STOP-ROP), a randomized, controlled trial. I: primary outcomes. Pediatrics. 2000;105(2):295-310. doi:10.1542/peds.105.2.295. PMID: 10654946.
3. Pediatric Eye Disease Investigator Group. A randomized trial of atropine vs. patching for treatment of moderate amblyopia in children. Arch Ophthalmol. 2002;120(3):268-78. doi:10.1001/archopht.120.3.268. PMID: 11879129.
4. Early Treatment For Retinopathy Of Prematurity Cooperative Group. Revised indications for the treatment of retinopathy of prematurity: results of the early treatment for retinopathy of prematurity randomized trial. Arch Ophthalmol. 2003;121(12):1684-94. doi:10.1001/archopht.121.12.1684. PMID: 14662586.
5. Haggerty H, Richardson S, Hrisos S, Strong NP, Clarke MP. The Newcastle Control Score: a new method of grading the severity of intermittent distance exotropia. Br J Ophthalmol. 2004;88(2):233-5. doi:10.1136/bjo.2003.027615. PMID: 14736781.
6. Buck D, Powell CJ, Rahi J, Cumberland P, Tiffin P, Taylor R, et al. The improving outcomes in intermittent exotropia study: outcomes at 2 years after diagnosis in an observational cohort. BMC Ophthalmol. 2012;12:1. doi:10.1186/1471-2415-12-1. PMID: 22257496.
7. Mintz-Hittner HA, Kennedy KA, Chuang AZ. Efficacy of intravitreal bevacizumab for stage 3+ retinopathy of prematurity. N Engl J Med. 2011;364(7):603-15. doi:10.1056/NEJMoa1007374. PMID: 21323540.
8. Stahl A, Lepore D, Fielder A, Fleck B, Reynolds JD, Chiang MF, et al. Ranibizumab versus laser therapy for the treatment of very low birthweight infants with retinopathy of prematurity (RAINBOW): an open-label randomised controlled trial. Lancet. 2019;394(10208):1551-1559. doi:10.1016/S0140-6736(19)31344-3. PMID: 31522845.

11

VITREORETINAL SURGERY

Narrow but examinable questions: when to operate, when endophthalmitis needs vitrectomy, which tamponade, and whether a drug can release traction.

STORY LINE DRVS (early vitrectomy for diabetic haemorrhage; see Chapter 4) → EVS (vitrectomise only light-perception endophthalmitis) → Silicone Study (oil or C3F8, not SF6) → MIVI-TRUST (ocriplasmin) → EVIAN (early vitrectomy for any post-operative endophthalmitis: feasible, promising, unproven).

DRVS

1985

Diabetic Retinopathy Vitrectomy Study

STUDY SNAPSHOT

See Chapter 4 · early vitrectomy vs deferral for a year · 616 eyes

QUESTION	Should severe diabetic vitreous haemorrhage be operated on early?
ANSWER	20/40 or better **25% vs 15%**; type 1 diabetes **36% vs 12%**.
CHANGED PRACTICE	Early surgery for type 1 diabetics.

EXAM TRAP Pre-dates endolaser, so its risk of losing light perception overstates modern risk.

SILICONE STUDY

1992

STUDY SNAPSHOT

Vitrectomy with silicone oil vs SF6 (Report 1) and vs C3F8 (Report 2) · retinal detachment with severe PVR

QUESTION	Which tamponade for PVR?
ANSWER	**Oil beat SF6**; **oil and C3F8 were equivalent**.
CHANGED PRACTICE	Use oil or C3F8, not SF6, for severe PVR.

EXAM TRAP A special advantage of oil in anterior PVR comes from secondary analyses only. Eyes with oil removed did better than those with oil retained (not randomised).

EVS

1995

Endophthalmitis Vitrectomy Study

STUDY SNAPSHOT

Immediate vitrectomy vs tap and inject; systemic antibiotics vs none (2×2) · 420 patients · within 6 weeks of cataract surgery

QUESTION	When does post-cataract endophthalmitis need vitrectomy?
ANSWER	Only at **light perception**: 20/40 or better **33% vs 11%**. Hand movements or better: no difference. Systemic antibiotics: no benefit.
CHANGED PRACTICE	Tap and inject for most patients; vitrectomy for light perception only.

EXAM TRAP Eyes with no light perception were excluded. Applies to post-cataract endophthalmitis only, not bleb-related, traumatic or endogenous.

MIVI-TRUST

2012

Microplasmin for IntraVitreous Injection: Traction Release without Surgical Treatment

STUDY SNAPSHOT

Intravitreal ocriplasmin vs sham · 652 eyes · vitreomacular traction (TG-MV-006 and -007)

QUESTION	Can a drug release vitreomacular traction?
ANSWER	Traction released at day 28 in **26.5% vs 10.1%**; macular holes closed in **40.6% vs 10.6%**.
CHANGED PRACTICE	A niche alternative to vitrectomy.

EXAM TRAP Endpoints were at day 28. Side effects include transient visual loss and dyschromatopsia.

NOW Now rarely used and no longer marketed in many countries.

EVIAN

2026

Early Vitrectomy and Intravitreal Antibiotics for Post-operative Exogenous Endophthalmitis

STUDY SNAPSHOT

Early vitrectomy + repeat intravitreal antibiotics (48–96 h) vs repeat antibiotics alone · 63 patients · endophthalmitis after any eye procedure, vision worse than 35 letters · open-label feasibility RCT · 24 weeks

QUESTION	Should post-operative endophthalmitis go for early vitrectomy, whatever the vision?
ANSWER	Feasible: **79%** of eligible patients randomised. Per-protocol median gain **+40 vs +13 letters**, not significant (p=0.139); retinal detachment **6.7% vs 24.2%**.
CHANGED PRACTICE	None yet; it justifies a phase 3 trial. EVS remains the evidence base.

EXAM TRAP A feasibility trial, not powered for efficacy. In the intention-to-treat analysis the median gains were similar (40 vs 44 letters). Unlike EVS, it included endophthalmitis after any procedure, not just cataract surgery.

GUIDELINE: AAO Preferred Practice Pattern on retinal breaks (2024 edition)

Management of vitreoretinal lesions, from Table 2 of the 2024 PPP.

What to do	Lesion
Treat promptly	• Acute symptomatic **horseshoe tears** • Acute symptomatic **dialyses**
Usually treat	• **Traumatic** retinal breaks
Consider treatment	• Asymptomatic **horseshoe tears**, unless there are signs of chronicity. **New in 2024**: earlier editions said these could usually be followed.
Usually no treatment	• Acute symptomatic **operculated holes** (treatment may not be necessary) • Asymptomatic **operculated holes** and **atrophic round holes** (treatment rarely recommended) • Asymptomatic **lattice with holes** • Asymptomatic **lattice without holes** (unless a PVD causes a horseshoe tear)
No consensus	• Asymptomatic dialyses • Atrophic holes or lattice when the **fellow eye** has had a detachment • Floaters • Prophylaxis of asymptomatic breaks **before cataract surgery**

NUMBERS TO REMEMBER

- Symptomatic horseshoe tear: **at least 50%** detach if untreated; **under 5%** after prompt laser or cryotherapy.
- Asymptomatic horseshoe tear: **about 5%** progress.
- Acute PVD with no break: **about 2%** develop one; review **within 6 weeks** if there is vitreous pigment, haemorrhage or traction.
- New breaks later: **5–14%** of patients with a break.
- Detachment after cataract surgery: **about 1%** in older series; **0.21%** at one year in the IRIS Registry.
- Fellow eye after one non-traumatic detachment: **about 10%**.

REFERENCES

1. The Diabetic Retinopathy Vitrectomy Study Research Group. Early vitrectomy for severe vitreous hemorrhage in diabetic retinopathy. Two-year results of a randomized trial. Diabetic Retinopathy Vitrectomy Study report 2. Arch Ophthalmol. 1985;103(11):1644-52. PMID: 2865943.
2. Silicone Study Group. Vitrectomy with silicone oil or sulfur hexafluoride gas in eyes with severe proliferative vitreoretinopathy: results of a randomized clinical trial. Silicone Study Report 1. Arch Ophthalmol. 1992;110(6):770-9. doi:10.1001/archopht.1992.01080180042027. PMID: 1596224.
3. Silicone Study Group. Vitrectomy with silicone oil or perfluoropropane gas in eyes with severe proliferative vitreoretinopathy: results of a randomized clinical trial. Silicone Study Report 2. Arch Ophthalmol. 1992;110(6):780-92. doi:10.1001/archopht.1992.01080180052028. PMID: 1596225.
4. Endophthalmitis Vitrectomy Study Group. Results of the Endophthalmitis Vitrectomy Study. A randomized trial of immediate vitrectomy and of intravenous antibiotics for the treatment of postoperative bacterial endophthalmitis. Arch Ophthalmol. 1995;113(12):1479-96. PMID: 7487614.
5. Stalmans P, Benz MS, Gandorfer A, Kampik A, Girach A, Pakola S, et al. Enzymatic vitreolysis with ocriplasmin for vitreomacular traction and macular holes. N Engl J Med. 2012;367(7):606-15. doi:10.1056/NEJMoa1110823. PMID: 22894573.
6. Muqit MM, Pavesio C, Wang Y, Cobb S, Spink C, Pizzo E, et al. Early vitrectomy and intravitreal antibiotics for post-operative exogenous endophthalmitis (EVIAN): a randomised control trial of feasibility. Commun Med (Lond). 2026;6(1): 42463897. doi:10.1038/s43856-026-01664-w. PMID: 42463897.
7. American Academy of Ophthalmology Retina/Vitreous Preferred Practice Pattern Committee. Posterior Vitreous Detachment, Retinal Breaks, and Lattice Degeneration Preferred Practice Pattern. San Francisco (CA): American Academy of Ophthalmology; 2024.

12

NEURO-OPHTHALMOLOGY

Mostly lessons in restraint: steroids speed recovery without changing it, decompression harms, and diagnosis can matter more than treatment.

STORY LINE Optic neuritis: ONTT (IV steroid for speed; avoid oral alone). NAION: IONDT (surgery harms). Trauma: NASCIS II → IONTS(no case for steroids or decompression) → CRASH. GCA: TABUL (ultrasound). IIH: IIHTT (acetazolamide works).

NASCIS II

1990

Second National Acute Spinal Cord Injury Study

STUDY SNAPSHOT

High-dose methylprednisolone vs naloxone vs placebo · acute spinal cord injury

QUESTION	Do mega-dose steroids help acute neural injury?
ANSWER	**No benefit** in the primary analysis; improvement only in a post hoc group treated within 8 hours.
CHANGED PRACTICE	The origin of high-dose steroids for traumatic optic neuropathy, by analogy.

EXAM TRAP A spinal cord trial, not an eye trial; its subgroup result is contested.

ONTT

1992

Optic Neuritis Treatment Trial

STUDY SNAPSHOT

IV methylprednisolone then oral prednisone vs oral prednisone alone vs placebo · 457 patients · acute optic neuritis

QUESTION	Do steroids help optic neuritis?
ANSWER	IV steroid **sped recovery** but final acuity was unchanged (fields, contrast and colour slightly better at 6 months). Oral prednisone alone was ineffective and **raised the risk of new episodes** (RR 1.79).
CHANGED PRACTICE	Treat for speed, not outcome; never oral prednisone alone at standard dose.

EXAM TRAP Brain MRI predicts MS: 5-year risk 16% with no lesions, 51% with three or more; 15-year risk 25% (no lesions) vs 72% (one or more).

IONDT

1995

Ischemic Optic Neuropathy Decompression Trial

STUDY SNAPSHOT

Optic nerve sheath decompression vs careful follow-up · 244 patients · NAION · 6 months

QUESTION	Does decompression surgery help NAION?
ANSWER	No, and it may harm: worse by 3 lines or more in **23.9% (surgery) vs 12.4%** (follow-up).
CHANGED PRACTICE	Decompression for NAION was abandoned.

EXAM TRAP **42.7%** of untreated patients improved by 3 lines or more: spontaneous improvement is common. Second-eye involvement about 15% at 5 years.

IONTS

1999

International Optic Nerve Trauma Study

STUDY SNAPSHOT

Observation vs IV steroid vs optic canal decompression · 133 patients · traumatic optic neuropathy · non-randomised

QUESTION	Do steroids or decompression help traumatic optic neuropathy?
ANSWER	**No clear benefit** from either.
CHANGED PRACTICE	Observation is the default.

EXAM TRAP Planned as an RCT but recruitment failed, so it cannot exclude a benefit.

CRASH

2004

Corticosteroid Randomisation After Significant Head injury

STUDY SNAPSHOT

48-hour methylprednisolone infusion vs placebo · 10,008 adults · significant head injury

QUESTION	Do steroids help head injury?
ANSWER	**Higher mortality** with steroid (21.1% vs 17.9% at 2 weeks).
CHANGED PRACTICE	Ended mega-dose steroids in head injury.

EXAM TRAP The safety caution that applies to any trauma patient with visual loss.

IIHTT

2014

Idiopathic Intracranial Hypertension Treatment Trial

STUDY SNAPSHOT

Acetazolamide (up to 4 g/day) + diet vs diet alone · 165 patients · mild visual loss in IIH · 6 months

QUESTION	Does acetazolamide help IIH?
ANSWER	Field MD improved **1.43 vs 0.71 dB** (p=0.05); papilloedema and CSF pressure improved too.
CHANGED PRACTICE	Acetazolamide plus weight loss is evidence-based for mild IIH.

EXAM TRAP A small field difference; the greatest benefit was in high-grade papilloedema.

TABUL

2016

Temporal Artery Biopsy vs ULtrasound in diagnosis of giant cell arteritis

STUDY SNAPSHOT

Temporal artery ultrasound vs biopsy · 381 patients · suspected GCA · prospective cohort, not randomised

QUESTION	Can ultrasound replace biopsy in suspected GCA?
ANSWER	Sensitivity: **biopsy 39%, ultrasound 54%**. Specificity: 100% vs 81%.
CHANGED PRACTICE	Ultrasound is a cheaper first test; biopsy is far less sensitive than assumed.

EXAM TRAP A negative biopsy does not exclude GCA.

NOW EULAR recommends ultrasound as first-line imaging.

REFERENCES

1. Bracken MB, Shepard MJ, Collins WF, Holford TR, Young W, Baskin DS, et al. A randomized, controlled trial of methylprednisolone or naloxone in the treatment of acute spinal-cord injury. Results of the Second National Acute Spinal Cord Injury Study. N Engl J Med. 1990;322(20):1405-11. doi:10.1056/NEJM199005173222001. PMID: 2278545.
2. Beck RW, Cleary PA, Anderson MM, Keltner JL, Shults WT, Kaufman DI, et al. A randomized, controlled trial of corticosteroids in the treatment of acute optic neuritis. The Optic Neuritis Study Group. N Engl J Med. 1992;326(9):581-8. doi:10.1056/NEJM199202273260901. PMID: 1734247.
3. Optic Neuritis Study Group. Multiple sclerosis risk after optic neuritis: final optic neuritis treatment trial follow-up. Arch Neurol. 2008;65(6):727-32. doi:10.1001/archneur.65.6.727. PMID: 18541792.
4. The Ischemic Optic Neuropathy Decompression Trial Research Group. Optic nerve decompression surgery for nonarteritic anterior ischemic optic neuropathy (NAION) is not effective and may be harmful. JAMA. 1995;273(8):625-32. PMID: 7844872.
5. Levin LA, Beck RW, Joseph MP, Seiff S, Kraker R. The treatment of traumatic optic neuropathy: the International Optic Nerve Trauma Study. Ophthalmology. 1999;106(7):1268-77. doi:10.1016/s0161-6420(99)00707-1. PMID: 10406604.
6. Roberts I, Yates D, Sandercock P, Farrell B, Wasserberg J, Lomas G, et al. Effect of intravenous corticosteroids on death within 14 days in 10008 adults with clinically significant head injury (MRC CRASH trial): randomised placebo-controlled trial.

Lancet. 2004;364(9442):1321-8. doi:10.1016/S0140-6736(04)17188-2. PMID: 15474134.

7. NORDIC Idiopathic Intracranial Hypertension Study Group; Wall M, McDermott MP, Kieburtz KD, Corbett JJ, Feldon SE, Friedman DI, et al. Effect of acetazolamide on visual function in patients with idiopathic intracranial hypertension and mild visual loss: the idiopathic intracranial hypertension treatment trial. JAMA. 2014;311(16):1641-51. doi:10.1001/jama.2014.3312. PMID: 24756514.

8. Luqmani R, Lee E, Singh S, Gillett M, Schmidt WA, Bradburn M, et al. The Role of Ultrasound Compared to Biopsy of Temporal Arteries in the Diagnosis and Treatment of Giant Cell Arteritis (TABUL): a diagnostic accuracy and cost-effectiveness study. Health Technol Assess. 2016;20(90):1-238. doi:10.3310/hta20900. PMID: 27925577.

13

EMERGING THERAPIES

Two therapies that act on mechanism rather than damage: gene replacement for a monogenic dystrophy, and a receptor blocker for thyroid eye disease.

STORY LINE Voretigene (first ocular gene therapy) and teprotumumab (first targeted drug for thyroid eye disease).

VORETIGENE NEPARVOVEC (LUXTURNA)

2017

STUDY SNAPSHOT

Subretinal voretigene vs control · 31 participants · biallelic RPE65 dystrophy · open-label phase 3

QUESTION	Can gene replacement restore function in RPE65 dystrophy?
ANSWER	Mobility-test score improved **1.8 vs 0.2** light levels.
CHANGED PRACTICE	First approved ocular gene therapy.

EXAM TRAP Needs confirmed biallelic RPE65 mutations and enough viable retinal cells.

NOW Chorioretinal atrophy after treatment has been reported; long-term follow-up is required.

TEPROTUMUMAB

2017 AND OPTIC 2020

OPTIC: Treatment of Graves' Orbitopathy (Thyroid Eye Disease) to Reduce Proptosis with Teprotumumab Infusions in a Randomized, Placebo-Controlled, Clinical Study

STUDY SNAPSHOT

IV teprotumumab every 3 weeks × 8 vs placebo · 88 patients (phase 2), OPTIC phase 3 · active moderate-to-severe TED

QUESTION	Can blocking IGF-1R treat active thyroid eye disease?
ANSWER	Response **69% vs 20%** (phase 2); proptosis response **83% vs 10%** (OPTIC).
CHANGED PRACTICE	First drug to reduce proptosis substantially without surgery.

EXAM TRAP Muscle spasm (32%), **hearing impairment** (5 of 41 in OPTIC, all resolved; persistent cases reported later) and hyperglycaemia; relapse after treatment occurs. Monitor glucose and hearing.

REFERENCES

1. Russell S, Bennett J, Wellman JA, Chung DC, Yu ZF, Tillman A, et al. Efficacy and safety of voretigene neparvovec (AAV2-hRPE65v2) in patients with RPE65-mediated inherited retinal dystrophy: a randomised, controlled, open-label, phase 3 trial. Lancet. 2017;390(10097):849-860. doi:10.1016/S0140-6736(17)31868-8. PMID: 28712537.
2. Smith TJ, Kahaly GJ, Ezra DG, Fleming JC, Dailey RA, Tang RA, et al. Teprotumumab for Thyroid-Associated Ophthalmopathy. N Engl J Med. 2017;376(18):1748-1761. doi:10.1056/NEJMoa1614949. PMID: 28467880.
3. Douglas RS, Kahaly GJ, Patel A, Sile S, Thompson EHZ, Perdok R, et al. Teprotumumab for the Treatment of Active Thyroid Eye Disease. N Engl J Med. 2020;382(4):341-352. doi:10.1056/NEJMoa1910434. PMID: 31971679.

In the treatment of Dry eye disease

Rx Lifanta

Lifitegrast Ophthalmic Solution 5% w/v

U.S. FDA APPROVED

A Novel Drug, Addresses Disease Pathology of Dry Eye

Significant improvement in[1]

- Subjective measures of ocular discomfort
- Superior and total corneal regions after 84 days

Significant reduction in the eye dryness score on day 14[2]



For the use of a Registered Medical Practitioner or a Hospital or a Laboratory only.

Disclaimer

This educational material is intended for healthcare professionals only. The content reflects expert opinion based on available evidence and clinical experience. Treatment decisions should be individualized based on patient-specific factors. Please refer to the approved prescribing information for complete product details.

An Initiative By

ajanta pharma

A TNOA EDITORIAL INITIATIVE

LENS
(LANDMARK, EVIDENCE, NUMBERS, SUMMARIES) IN OPHTHALMOLOGY

The evidence that changed practice



Dr. Pranessh Ravi, MS, DNB, MNAMS, FMRF (Cornea),MRCS, FRCS (Glasgow),FAICO (Cornea), FAICO (Refractive), is a Consultant in Cornea and Phaco-Refractive Surgery at The Eye Foundation, Hosur, Tamil Nadu, India.

He serves as the **LENS Author & Editor** with a strong interest in academic publishing, clinical research, and postgraduate ophthalmic education.

Through his scholarly contribution to *LENS in Ophthalmology: The Evidence That Changed Practice*, he has brought together pivotal clinical trials across ophthalmic subspecialties in a concise, structured, and examination-oriented resource. This initiative reflects his commitment to strengthening clinical reasoning, encouraging evidence-based learning, and helping postgraduate students and practising ophthalmologists better understand the research that has shaped modern ophthalmic care.



Dr. Prasanna Venkatesh Ramesh, MS (Gold Medalist), DNB, FACS, MNAMS, FICO (Glaucoma), FAICO (Glaucoma), and FAICO (Phaco) (Gold Medalist), is a distinguished glaucoma specialist, academician, researcher, and medical educator at Mahathma Eye Hospital, Tiruchirappalli, Tamil Nadu, India.

He serves as the **Editor-In-Chief of the TNOA Journal of Ophthalmic Science and Research & LENS Executive Editor** and is actively involved in advancing ophthalmic research, postgraduate education, and surgical training. His areas of expertise include minimally invasive glaucoma surgery (MIGS), innovative surgical techniques, and the integration of emerging technologies into ophthalmic education.

A strong advocate of evidence-based medicine, Dr. Prasanna emphasises scientific literacy, critical appraisal, and the practical application of clinical research. This academic association with *LENS in Ophthalmology: The Evidence That Changed Practice* reflects his commitment to making landmark clinical evidence accessible, meaningful, and relevant to postgraduate students, young ophthalmologists, and practising clinicians.